Journal of Medical Imaging & Case Reports

https://doi.org/10.17756/micr.2021-070

Case Report

Open Access

Cerebrospinal Fluid Leak Post-Nasopharyngeal Swab for COVID-19: Two Case Reports and Literature Review

Abdullah Abohimed[1], Bader Almanna[1], Abdulrahman Baashar[1], Naif Almontashiri[2], Ashraf Al Harthi[3], Muhammad Ejaz Ahmed[1] and Makki Almuntashri[1]

[1]*Department of Medical Imaging, King Abdulaziz Medical City, King Saud bin Abdulaziz University for Health Sciences, King Abdullah International Medical Research Center, Ministry of National Guard, Riyadh, Saudi Arabia*

[2]*Center for Genetics and Inherited Diseases, Taibah University, Medina, Saudi Arabia.*

[3]*Department of Neurology, King Abdulaziz Medical City, King Saud bin Abdulaziz University for Health Sciences, King Abdullah International Medical Research Center, Ministry of National Guard, Riyadh, Saudi Arabia.Arabia.*

***Correspondence to:**
Dr. Bader Almanna
Department of Medical Imaging
King Abdulaziz Medical City, King Saud bin Abdulaziz University for Health Sciences,
King Abdullah International Medical Research Center, Ministry of National Guard
Riyadh, Saudi Arabia.
E-mail: baderalmannaa@gmail.com

Received: November 02, 2021
Accepted: February 14, 2022
Published: February 16, 2022

Citation: Abohimed A, Almanna B, Baashar A, Ejaz M, Almuntashri M et al. 2022. Cerebrospinal Fluid Leak Post-Nasopharyngeal Swab for COVID-19: Two Case Reports and Literature Review. *J Med Imaging Case Rep* 5(2): 35-38.

Copyright: © 2021 Abohimed et al. This is an Open Access article distributed under the terms of the Creative Commons Attribution 4.0 International License (CC-BY) (http://creativecommons.org/licenses/by/4.0/) which permits commercial use, including reproduction, adaptation, and distribution of the article provided the original author and source are credited.

Published by United Scientific Group

Abstract

The Coronavirus disease 2019 (COVID-19) has had a global impact with devastating implications on the economic, social, educational, and medical fronts. Approximately, 100 million cases of COVID-19 have been diagnosed as of writing this paper [1]. Very few sampling adverse events were described in literature. In this article, we present two cases of traumatic cerebrospinal fluid (CSF) leakage post-nasal swab for COVID-19.

Keywords

Cerebrospinal fluid leakage, Coronavirus, Nasopharyngeal Swab, Idiopathic Intracranial Hypertension

List of abbreviations

COVID-19: Coronavirus Disease 2019; **CSF**: Cerebrospinal Fluid; **MRI**: Magnetic Resonance Imaging; **CT**: Computed Tomography; **FLAIR:** Fluid-attenuated Inversion Recovery **FIESTA:** Fast Imaging Employing Steady-state Acquisition; **IIH**: Idiopathic Intracranial Hypertension

Introduction

In confirming the diagnosis of COVID-19, two types of laboratory tests exist: molecular and antigen tests, to detect viral genome and proteins, respectively [2]. Nasopharyngeal swabs are the most widely performed method for collecting samples for the detection of COVID-19. Performing a proper nasal swab is crucial in the screening of Coronavirus infection and requires an intimate knowledge of nasal anatomy [3].

Case Report

First case:

A 45-year-old female patient with remote history of conservatively treated idiopathic intracranial hypertension (IIH) had undergone routine COVID-19

testing mid-December, 2020. Two days later, she presented to the emergency department with rhinorrhea, mild cough, and severe headache unrelieved by analgesia. A sample was taken from the clear nasal discharge and was found to be positive for glucose. A non-enhanced computed tomography (CT) scan revealed an opacified right sphenoid sinus without ominous surrounding lesion (Figure 1). A few days later, high resolution magnetic resonance imaging (MRI) including fluid-attenuated inversion recovery (FLAIR) and fast imaging employing steady-state acquisition (FIESTA) sequences confirmed CSF leak through skull base defect filling the sphenoid sinus. (Figure 2 and 3). Thin-cut paranasal sinus CT confirmed the osseous defect. (Figure 4). Incidentally, MRI also demonstrated features compatible with idiopathic intracranial hypertension (IIH).

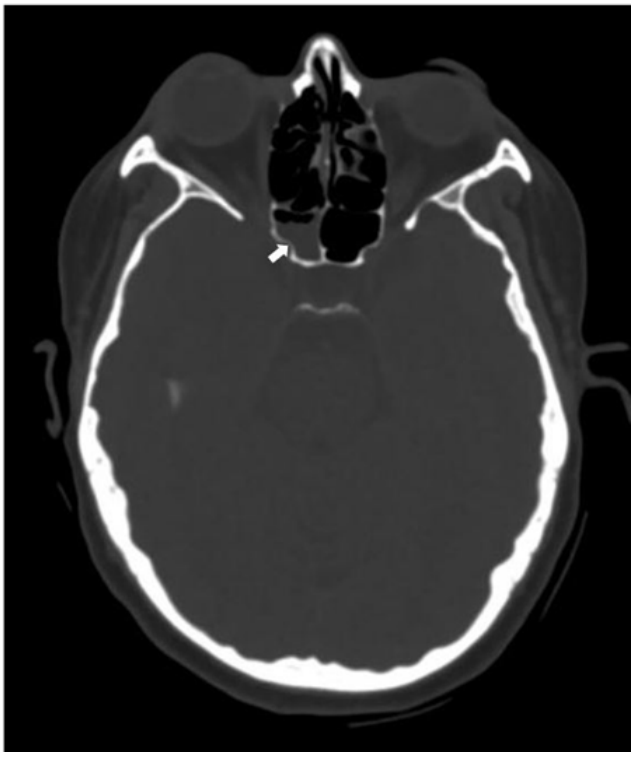

Figure 1: Axial non-enhanced CT scan of the head demonstrates asymmetrical opacification of the right-side of the sphenoid sinus (white arrow).

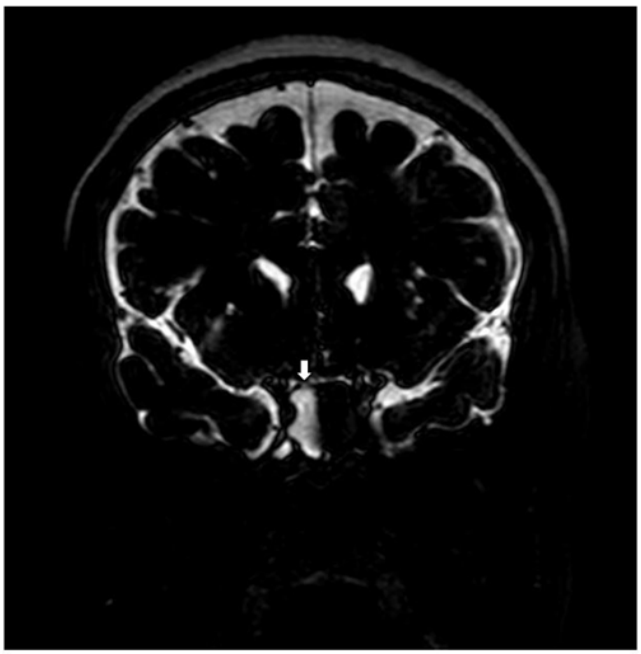

Figure 3: Coronal T2-FIESTA MRI of the brain shows clear defect through the planum sphenoidale (white arrow).

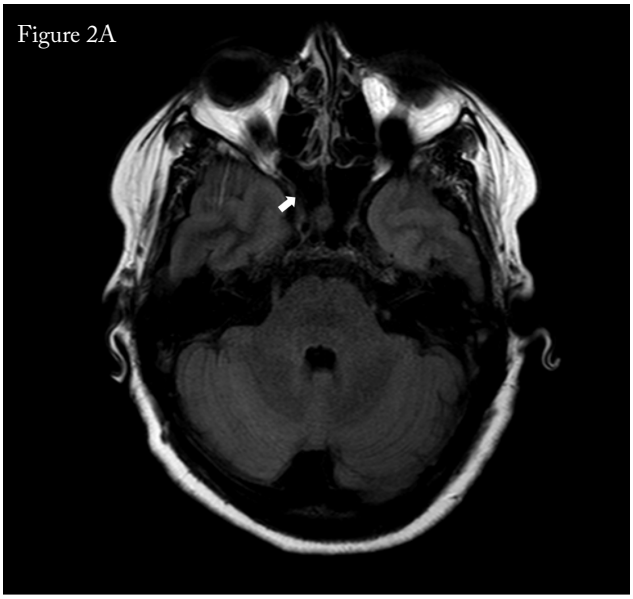

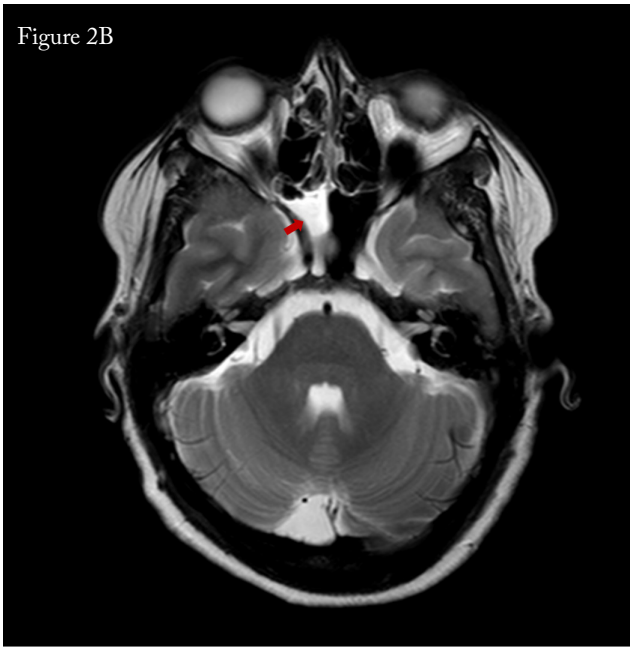

Figure 2A: Axial T2-FLAIR and **Figure 2B:** T2-weighted MRI of the brain demonstrate fluid within the right-side of the sphenoid sinus that is high signal on T2WI (red arrow) and a low signal on T2-FLAIR (white arrow), consistent with CSF.

Second case

A 36-year-old female patient, who lives in a rural town, regularly follows up with Obstetrics and Gynecology for her infertility, presented to our hospital for a regular follow-up for

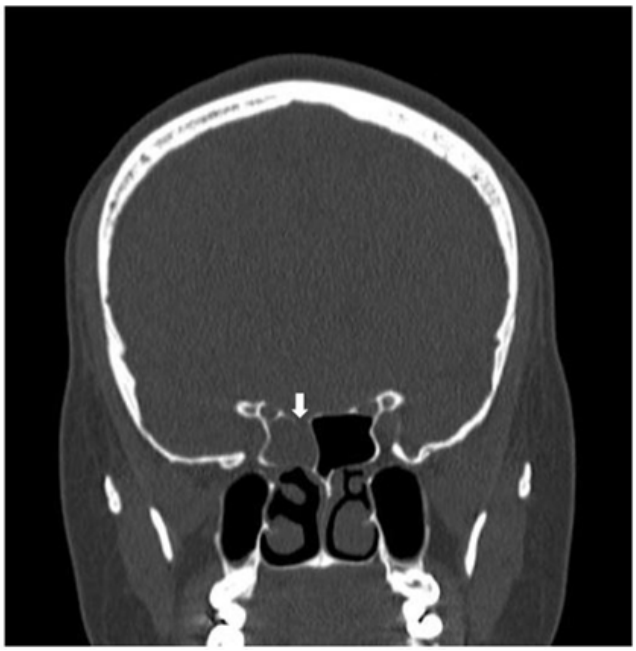

Figure 4: Coronal thin section non-enhanced bone window CT scan of the head demonstrates small bony defect along the medial aspect of the right sphenoid planum (white arrow).

which she had to be screened for COVID-19. Ten days later, she presented to our emergency department complaining of headaches and clear nasal discharge. She noted that her nasal swab was extremely painful. Her past medical history was remarkable for chronic headaches. An MRI back in 2018 showing classic radiologic signs of IIH (Figure 5). β-2 transferrin testing from the right nasal cavity confirmed the presence of



Figure 5: Axial T2-weighted MRI of the brain reveals features compatible with IIH in the form of an empty sellaturcica (white arrow), flattening of the posterior sclera, and widening of the CSF spaces around the optic nerve (red arrows).

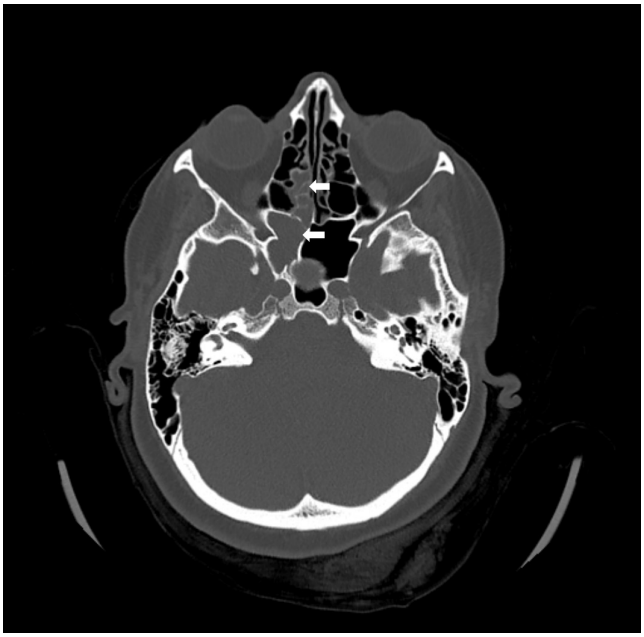

Figure 6: Axial non-enhanced CT scan of the head shows opacification of both the posterior ethmoid, and right side of the sphenoid sinus (white arrows).



Figure 7: Coronal non-enhanced CT scan of the head reveals the suspected osseous defect at the cribriform plate (white arrow).

CSF. CT scan of the head showed opacification of the posterior ethmoid and right sphenoid sinuses, as well as bony defect along the cribriform plate of ethmoid (Figure 6 and 7).

Discussion

The literature regarding complications of nasopharyngeal swab is scarce. A few adverse events were observed according to a large cohort from northern Germany where a total of 11,476 deep nasal and oropharyngeal swabs were tested [4]. There are

limited reports of traumatic CSF leak post COVID-19 nasopharyngeal swab in the literature. The first case was reported by Sullivan et.al. [5] It was postulated since their patient had a preexisting defect through the fovea ethmoidalis, associated with an encephalocele, the swab itself most likely injured the encephalocele as opposed to violating the skull base. [5] Another reports showed preexisting encephalocele and congenital meningocele which happened to be prone to mucosal damage surrounding the herniated brain tissue causing traumatic CSF leak when the nasal swab was inserted incorrectly. [6, 7] Two cases, however, had no radiological preexisting bony defect prior to the swab. The tip had violated the skull which resulted in projection of an encephalocele. [8, 9] Two papers showed direct injury to the cribriform plate without history of IIH or known preexisting bony defect without post-swab brain herniation [10, 11]. In this paper, we present two cases of traumatic CSF leak post-nasal swab for COVID-19. Persistent pulsatile CSF in the setting of IIH is suggested to remodel and erode the thin bones at the base of the skull. [12] The causal relationship between IIH and spontaneous CSF leak is well established in the literature [13]. Both of our patients have known history of IIH. Furthermore, the visualized skull base defects were not apparent on previous imaging. Therefore, we hypothesize that the nasal swab itself may have injured the skull base and resulted in traumatic CSF leakage.

Conclusion

We present two additional cases of traumatic CSF leak post-nasal swab for COVID-19. Our report further highlights the expected radiological findings and the clinical importance of acquiring an accurate and thorough history from the patient prior to performing nasal swabs as a prerequisite. Alternative methods including oropharyngeal swab should be considered in patients with signs and symptoms of IIH and known preexisting skull base defects. We believe reporting post-nasopharyngeal swab complications will improve sampling technique practice.

Conflict of Interest

The authors declare no conflict of interest.

Acknowledgement

None.

References

1. COVID-19 Dashboard by the Center for Systems Science and Engineering (CSSE) at Johns Hopkins University (JHU). [Accessed February 28, 2021].
2. United States Food & Drug Administration (FDA). A Closer Look at COVID-19 Diagnostic Testing. [Accessed February 28, 2021].
3. Kinloch NN, Shahid A, Ritchie G, Dong W, Lawson T, et al. 2020. Evaluation of nasopharyngeal swab collection techniques for nucleic acid recovery and participant experience: recommendations for COVID-19 diagnostics. *Open Forum Infect Dis* 7(11): ofaa488. https://doi.org/10.1093/ofid/ofaa488
4. Foh B, Borsche M, Balck A, Taube S, Rupp J, et al. 2020. Complications of nasal and pharyngeal swabs: a relevant challenge of the COVID-19 pandemic? *Eur Respir J* 57(4):2004004. https://doi.org/10.1183/13993003.04004-2020
5. Sullivan CB, Schwalje AT, Jensen M, Li L, Dlouhy BJ, et al. 2019. Cerebrospinal fluid leak after nasal swab testing for coronavirus disease 2019. *JAMA Otolaryngol Head Neck Surg* 146(12): 1179-1181. https://doi.org/10.1001/jamaoto.2020.3579
6. Rajah J, Lee J. 2021. CSF rhinorrhoea post COVID-19 swab: a case report and review of literature. *J Clin Neurosci* 86: 6-9. https://doi.org/10.1016/j.jocn.2021.01.003
7. Holmes A, Allen B. 2021. Case report: an intracranial complication of COVID-19 nasopharyngeal swab. *Clin Pract Cases Emerg Med* 5(3): 341-344. https://doi.org/10.5811/cpcem.2021.5.52232
8. Paquin R, Ryan L, Vale FL, Rutkowski M, Byrd JK. 2021. CSF leak after covid-19 nasopharyngeal swab: a case report. *Laryngoscope* 131(9): 1927-1929. https://doi.org/10.1002/lary.29462
9. Sadashiva A, Panji N, Shivappa L. 2021. CSF Leak Following Nasal Swab Testing For COVID-19. *Neurol India* 69(5): 1467-1468. https://doi.org/10.1001/jamaoto.2020.3579
10. Mistry S, Walker W, Earnshaw J, Cervin A. 2021. COVID-19 swab-related skull base injury. *Med J Aust* 214(10): 457- 459. https://doi.org/10.5694/mja2.51082
11. Knížek Z, Michálek R, Vodicka J, Zdobinská P. 2021. Cribriform plate injury after nasal swab testing for COVID-19. *JAMA Otolaryngol Head Neck Surg* 147(10): 915-917. https://doi.org/10.1001/jamaoto.2021.2216
12. Bidot S, Levy JM, Saindane AM, Oyesiku NM, Newman NJ, et al. 2019. Do most patients with a spontaneous cerebrospinal fluid leak have idiopathic intracranial hypertension? *J Neuroophthalmol* 39(4): 487-495. https://doi.org/10.1097/wno.0000000000000761
13. Perez MA, Bialer OY, Bruce BB, Newman NJ, Biousse V. 2013. Primary spontaneous cerebrospinal fluid leaks and idiopathic intracranial hypertension. *J Neuroophthalmol* 33(4): 330-337. https://doi.org/10.1097/wno.0b013e318299c292