Journal of Medical Imaging & Case Reports

https://doi.org/10.17756/micr.2023-099

Case Report

Open Access

Stress Cardiomyopathy Secondary to Pheochromocytoma: A Case Report

Catalina Jaramillo[1*], Danai Kitkungvan[1], Laura Ocacio[2] and Daniel Ocazionez[1]

[1]The University of Texas Health Science Center, Houston, USA
[2]Memorial Hermann-Texas Medical Center, USA

***Correspondence to:**
Catalina Jaramillo
The University of Texas Health Science Center, Houston, USA.
E-mail: catalina.jaramillofranco@uth.tmc.edu

Received: November 08, 2023
Accepted: December 01, 2023
Published: December 05, 2023

Citation: Jaramillo C, Kitkungvan D, Ocacio L, Ocazionez D. 2023. Stress Cardiomyopathy Secondary to Pheochromocytoma: A Case Report. *J Med Imaging Case Rep* 7(2): 61-64.

Copyright: © 2023 Jaramillo et al. This is an Open Access article distributed under the terms of the Creative Commons Attribution 4.0 International License (CCBY) (http://creativecommons.org/licenses/by/4.0/) which permits commercial use, including reproduction, adaptation, and distribution of the article provided the original author and source are credited.

Published by United Scientific Group

Abstract

Stress cardiomyopathy (SCM) mimics acute myocardial infarction, it's part of the Myocardial Infarction with Non-Obstructive Coronary Artery (MINOCA) differential and occurs after emotional or physical stress. Left ventricle ballooning results in acute heart failure. A case of SCM with incidental finding of pheochromocytoma is presented. Pheochromocytoma is closely related to SCM and should be diagnosed as a single entity. Echocardiography and Cardiac magnetic resonance (CMR) are fundamental in the diagnosis. CMR cine sequences aid in the assessment of wall motion abnormalities, CMR T1 and T2 mapping protocol and Late gadolinium enhancement (LGE) help distinguish SCM from other fatal etiologies.

Keywords

Cardiomyopathy, Pheochromocytoma, Echocardiogram, Takotsubo syndrome

Introduction

Stress-induced cardiomyopathy (SCM), also known as Takotsubo syndrome, is an acute cardiac stress phenomenon which leads to ventricular dysfunction and is triggered by intense emotional or physical stress [1, 2]. This entity is characterized by transient wall motion abnormalities due to left ventricle (LV) dilatation; this results in reversible heart failure [1, 3]. SCM presents similar to Acute coronary syndrome (ACS), with chest pain, dyspnea or syncope, elevation of cardiac biomarkers and electrocardiographic abnormalities [2, 4]. This condition is part of the Myocardial infarction with non obstructive coronary artery (MINOCA) differential in which patients present with acute coronary syndrome but have no evidence of obstructive coronary artery disease [3, 5].

The name Takotsubo syndrome derives from a Japanese octopus fishing trap which resembles the ballooned left ventricle [3, 4]. Cardiac magnetic resonance (CMR) due to its multisequence and multiplanar capabilities, is fundamental for the diagnosis as it can easily distinguish this entity from other MINOCA conditions such as myocarditis.

Case Presentation

A 64-year-old female presented to the emergency department with acute chest pain. Chest pain started 2 days ago with nonspecific localization; preceding abdominal pain several weeks before is also described. Past medical history included labile hypertension. She was a lifetime nonsmoker and there was no family history of heart disease. She presented with diffuse ST segment changes in the electrocardiogram and elevation in troponin enzymes, acute coronary syndrome was suspected. Physical examination revealed hypertension (163/97 mmHg) and

tachycardia (112 beats per minute). The patient was afebrile, with a Glasgow coma scale of 15/15, she had unlabored breathing, symmetric chest expansion, and no pathological pulmonary sounds. The abdomen was mildly distended and there was no abdominal pain with palpation. She was moving all her extremities and pulses were 2+ and symmetrical. Laboratory results showed mild hyponatremia, normal arterial gases, elevated creatinine, anemia, and leukocytosis. Emergent transthoracic echocardiography was performed and showed apical akinesis. The patient was later taken to the Cath lab for coronary angiography which demonstrated non obstructive coronary arteries (Figure 1a and 1b). The patient underwent cardiac magnetic resonance (Figure 2, figure 3a and 3b, and figure 4a and 4b) which was consistent with stress-induced "Takotsubo" cardiomyopathy. Incidentally, CMR also demonstrated a large heterogeneous right adrenal mass. Contrast-enhanced computed tomography of the abdomen showed a heterogenous mass with a hemorrhagic component, diagnosed as pheochromocytoma (Figure 5a and 5b). There was concern for active bleeding from the adrenal gland mass, interventional radiology attempted embolization, but the vessel was too small to be successful. The patient was given one unit of packed red blood cells and a crystalloid fluid bolus, when she was more stable treatment for cardiomyopathy was adjusted with amiodarone and metoprolol tartrate. She was discharged in stable condition, normotensive, and without abdominal or chest pain. Electrolyte abnormalities, creatinine, leukocytosis, and anemia were corrected. The healthcare team prescribed the patient an adrenal functional panel test, which included 24-hour urine metanephrines, aldosterone, ACTH, cortisol, and renin. The patient was advised to follow up with the medical team and surgeon, adrenalectomy was planned. Unfortunately, the patient moved out of the city and didn't receive follow-up care.

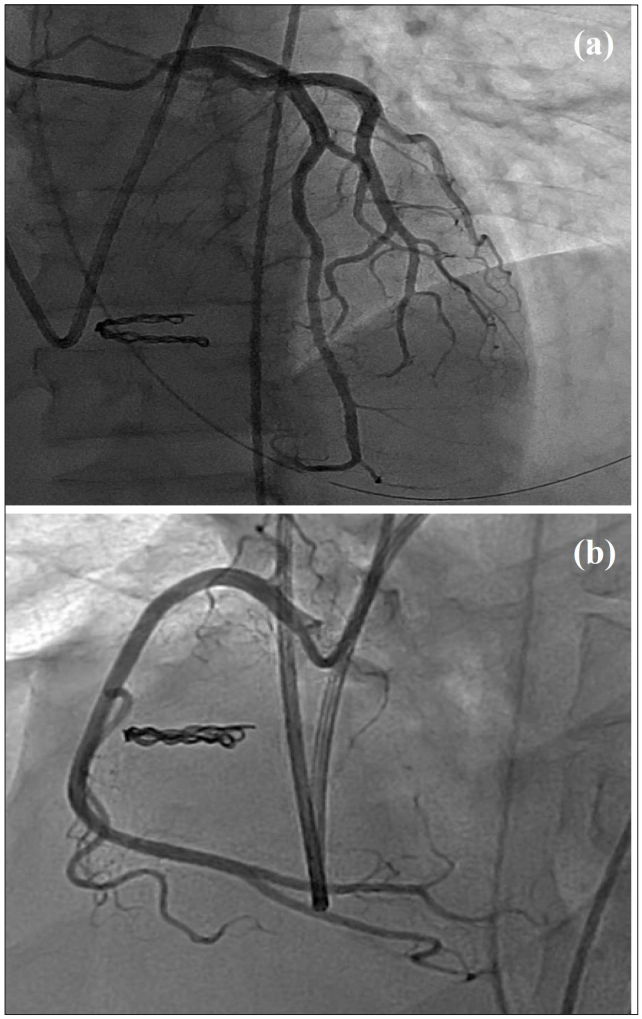

Figure 1: (a) Left and **(b)** Right coronary angiogram images without evidence of stenosis.

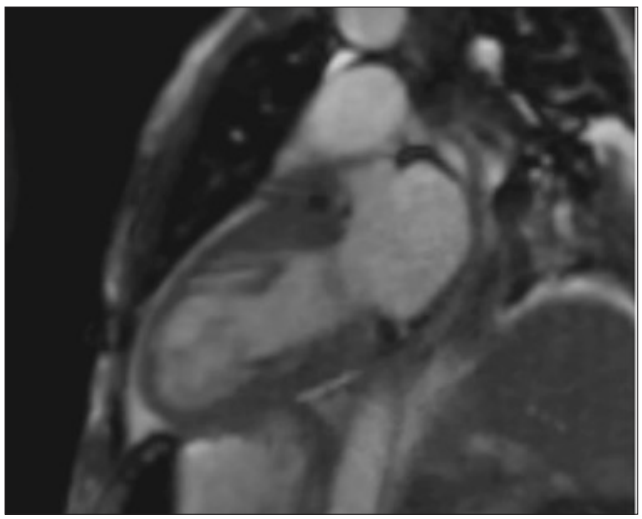

Figure 2: Two chamber steady state free precision image which shows apical ballooning.

Discussion

First reported in Japan in 1990, Takotsubo syndrome is now recognized globally, yet remains significantly underappreciated and frequently misdiagnosed [1, 4]. SCM prevalence is constantly increasing, representing 1 - 3% of all ACS and 5 - 6% of ST segment elevation myocardial infarction in women [3]. Over 85% of patients are women, with a 5-fold higher risk in women over 55 years of age [3, 6]. Triggers include emotional/psychological stress and physical stress (strenuous activity, medical conditions, and surgeries) [3]. 70% of patients had a preceding trigger factor [6].

The exact pathophysiology of the disease isn't described, but it is believed the adrenergic system plays an important role in the development of disease. Blood borne catecholamine myocardial toxicity is described, as well as LV outlet obstruction and diffuse vasospasm with cardiac microvascular dysfunction [1, 3, 6]. This intense acute stress results in transient LV malfunctioning, which in the majority of patients resolves.

Numerous diagnostic criteria have been suggested; the Heart Failure Association of the European Society of Cardiology diagnostic criteria for Takotsubo Syndrome, the International Takotsubo Diagnostic Criteria (InterTAK), and the Revised Mayo Clinic Criteria are the most frequently employed. However, there remains an absence of a definitive consensus regarding whether pheochromocytoma should serve as an exclusion criterion for SCM [1, 4]. Some of these newer guidelines include pheochromocytoma and neurological disorders (subarachnoid hemorrhage and seizures) as a secondary trigger for SCM [1, 4]. Pheochromocytoma

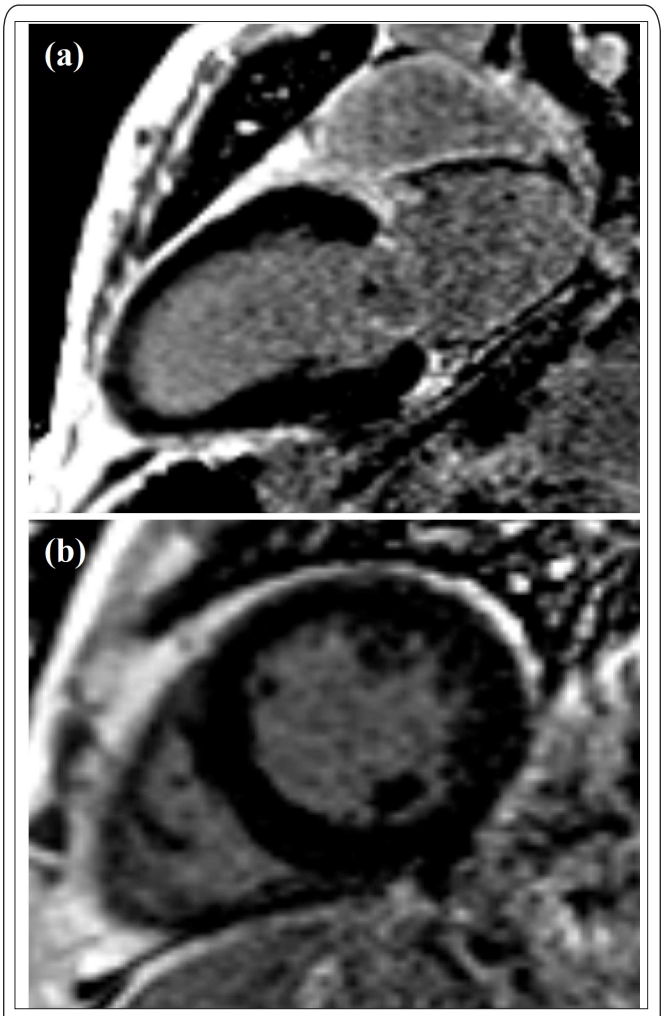

Figure 4: (a) 2 chamber and **(b)** 4 short axis delayed enhancement Cardiac MRI which demonstrate no abnormal delayed enhancement.

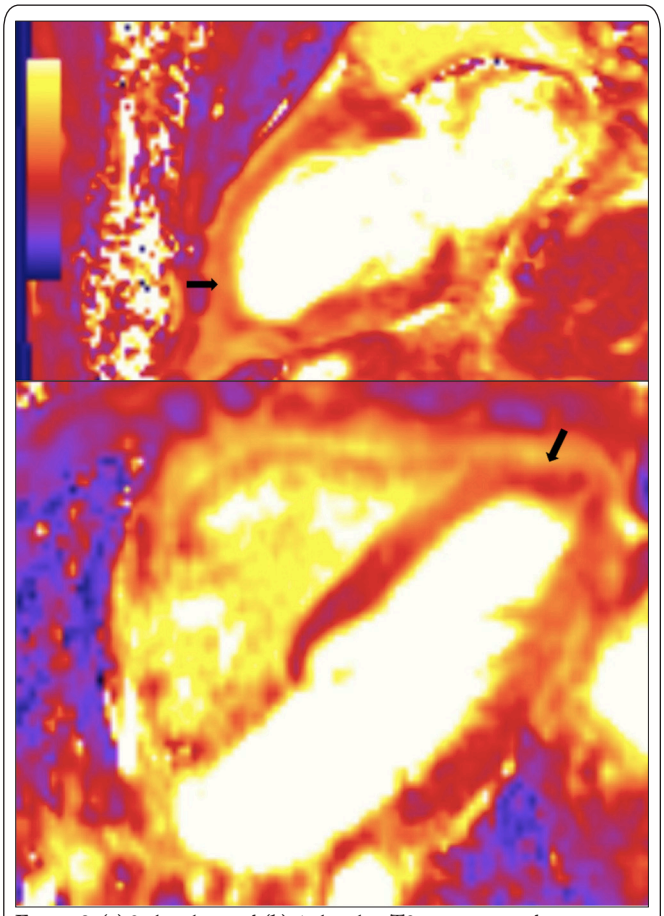

Figure 3: (a) 2 chamber and **(b)** 4 chamber T2 mapping cardiac magnetic resonance images which illustrate increased T2 signal in the apical and mid segment (black arrows) consistent with edema.

and SCM are closely related, with high levels of circulating catecholamines, and it should be diagnosed as one entity and not as a comorbidity [7, 8]. There is a profound pathophysiological connection between the two, and unlike other comorbidities, pheochromocytoma creates *reversible* LV dysfunction [7]. Takotsubo syndrome with underlying pheochromocytoma has been associated with worse prognosis and complications, so the association between the two should be acknowledged [8, 9].

For the diagnosis, patients must have electrocardiogram changes which resemble ACS including ST segment elevation or T wave inversion [2]. Cardiac biomarkers are also elevated, with 90% of patients with SCM having elevated troponin levels [5]. Brain natriuretic peptide and creatine kinase are usually also elevated [2, 5]. Non-obstructive coronary angiography and characteristic findings on non-invasive imaging confirm the diagnosis.

Transthoracic echocardiography is the first line imaging modality. It depicts the pathognomonic LV wall motion abnormalities with apical ballooning in 75% of patients in addition to decreased ejection fraction [5]. Decreased LV ejection fraction aids in the identification of high-risk patients, as it is an independent risk factor for major cardiovascular complications [10, 11]. Additional techniques such as peak systolic strain and speckle tracking can add additional information in regard to contractility and dynamics [3].

CMR due to its multisequence and multiplanar capabilities is a valuable non-invasive modality for diagnosis, detecting complications and biventricular involvement. Cine CMR sequences are appropriate to evaluate ventricular function and detect wall motion abnormalities. It is also effective in demonstrating LV outflow tract obstruction and mitral regurgitation if assessed with velocity imaging for outflow tract gradient. Feature/tissue tracking CMR has been used recently for myocardial deformation quantification and could be used as a prognostic indicator [10]. Myocardial edema can be detected in CMR using T2-weighted imaging protocol, which can distinguish SCM from conditions that permanently damage the myocardium like myocarditis and myocardial infarction [3, 6]. Myocarditis can also be differentiated by its myocardial edema pattern, which tends to be diffuse and heterogenous, in SCM the signal distribution is transmural and circumferential [10]. Fast spin echo with triple-inversion recovery sequence allows for contrast signal to differentiate edematous tissue, which regularly correlates with the dysfunctional ventricular areas in cine CMR [10, 12]. T2-weighted triple IR imaging may be susceptible to artifacts arising from bleeding, motion, and arrhythmias. This is why techniques employing motion correction algorithms, such as extracellular volume mapping, along with parametric T1 or T2 mapping, are the preferred methods [10]. Late gadolinium

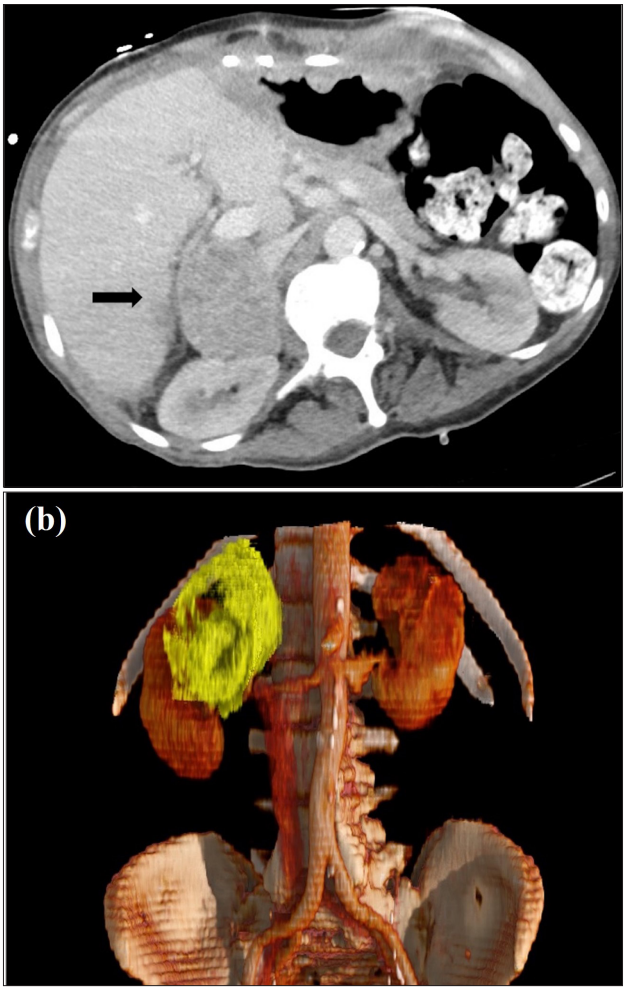

Figure 5: (a) Axial contrast enhanced CT images demonstrating a heterogenous and enhancing right adrenal mass (black arrow). and **(b)** 3D Coronal Rendering of adrenal mass.

enhancement (LGE) is suggestive of fibrosis and scarring from injury and inflammation. Initially, the absence of LGE was a distinguishing characteristic of stress cardiomyopathy, separating it from conditions like myocardial infarction or myocarditis, but recent studies have shown SCM does present with LGE, but with a lesser degree of intensity compared to other conditions [10, 12]. Cases that present with LGE may be linked to a higher degree of edema and cardiogenic shock [12, 13]. CRM is elemental in the diagnosis of SCM presenting with ACS and history of old myocardial infarction because it can distinguish chronic lesions.

There is no standardized treatment, support is provided until LV function spontaneously recovers, often within 3 - 4 weeks [3, 5]. Milder cases are managed with standard heart failure care, with antihypertensive drugs and diuretics when necessary. Aspirin and anticoagulation may be necessary if additional risk factors (LV thrombus) [5, 6]. Patients with cardiogenic shock may require inotropes and vasopressors [1, 3]. Treating underlying triggers is crucial to prevent recurrence.

The prognosis is good, with 95% of patients regaining normal LV function [1]. Recurrence rates are low (1.5% in one year, 5% at six years) [1, 3]. Death occurs in 5% of patients and is more common in hemodynamically unstable patients (5%).

Conclusion

SCM has a rising incidence and must be a differential diagnosis in ACS, especially in women with triggers. Pheochromocytoma should not be an exclusion criterion for SCM but considered a reversible cause. Diagnosis relies on echocardiography and CMR which distinguishes it from other fatal and permanent conditions. Further research and clinical trials are necessary to refine diagnosis and treatment guidelines.

Acknowledgements

None.

Conflicts of Interest

None.

References

1. Boyd B, Solh T. 2020. Takotsubo cardiomyopathy: review of broken heart syndrome. *J Am Acad Phys Assist* 33(3): 24-29. https://doi.org/10.1097/01.JAA.0000654368.35241.fc
2. Díaz-Navarro R. 2021. Takotsubo syndrome: the broken-heart syndrome. *Br J Cardiol* 28(1): 11. https://doi.org/10.5837/bjc.2021.011
3. Matta A, Delmas C, Campelo-Parada F, Lhermusier T, Bouisset F, et al. 2022. Takotsubo cardiomyopathy. *Rev Cardiovasc Med* 23(1): 38. https://doi.org/10.31083/j.rcm2301038
4. Ghadri JR, Wittstein IS, Prasad A, Sharkey S, Dote K, et al. 2018. International expert consensus document on Takotsubo syndrome (part I): clinical characteristics, diagnostic criteria, and pathophysiology. *Eur Heart J* 39(22): 2032-2046. https://doi.org/10.1093/eurheartj/ehy076
5. Amin HZ, Amin LZ, Pradipta A. 2020. Takotsubo cardiomyopathy: a brief review. *J Med Life* 13(1): 3-7. https://doi.org/10.25122/jml-2018-0067
6. Y-Hassan S, Tornvall P. 2018. Epidemiology, pathogenesis, and management of takotsubo syndrome. *Clin Auton Res* 28: 53-65. https://doi.org/10.1007/s10286-017-0465-z
7. Guglin M. 2016. Pheochromocytoma and takotsubo. *Int J Cardiol* 202: 952. https://doi.org/10.1016/j.ijcard.2015.10.031
8. Santoro F, Ferraretti A, Tarantino N, Di Biase M, Brunetti ND. 2016. Takotsubo cardiomyopathy and pheochromocytoma: "what therefore God hath joined together, let not man put asunder". *Int J Cardiol* 203: 449. https://doi.org/10.1016/j.ijcard.2015.10.191
9. Yalta K, Yalta T, Yetkin E. 2022. Pheochromocytoma and takotsubo syndrome: an ominous duo. *Anatol J Cardiol* 26(8): 668. https://doi.org/10.5152/AnatolJCardiol.2022.2038
10. Zghyer F, Botheju WSP, Kiss JE, Michos ED, Corretti MC, et al. 2022. Cardiovascular imaging in stress cardiomyopathy (takotsubo syndrome). *Front Cardiovasc Med* 8: 799031. https://doi.org/10.3389/fcvm.2021.799031
11. Citro R, Rigo F, Previtali M, Ciampi Q, Canterin FA, et al. 2012. Differences in clinical features and in-hospital outcomes of older adults with tako-tsubo cardiomyopathy. *J Am Geriatr Soc* 60(1): 93-98. https://doi.org/10.1111/j.1532-5415.2011.03730.x
12. Eitel I, von Knobelsdorff-Brenkenhoff F, Bernhardt P, Carbone I, Muellerleile K, et al. 2011. Clinical characteristics and cardiovascular magnetic resonance findings in stress (takotsubo) cardiomyopathy. *JAMA* 306(3): 277-286. https://doi.org/10.1001/jama.2011.992
13. Wu KC, Weiss RG, Thiemann DR, Kitagawa K, Schmidt A, et al. 2008. Late gadolinium enhancement by cardiovascular magnetic resonance heralds an adverse prognosis in nonischemic cardiomyopathy. *J Am Coll Cardiol* 51(25): 2414-2421. https://doi.org/10.1016/j.jacc.2008.03.018