Journal of Medical Imaging & Case Reports

https://doi.org/10.17756/micr.2024-104

Case Report

Open Access

A Rare Case of Mature Cystic Teratoma with Infantile Hemangioma and Pericardial Invasion

Juka S. Kim[1,2], Isabel K. Eng[2], Janis M. Yee[3], Margaret Lee[2,4], Monica Deshmukh[2,4] and Mariam Thomas [2,4*]

[1]Department of Medicine, Stanford University, Stanford, California, United States
[2]David Geffen School of Medicine, University of California, Los Angeles, California, United States
[3]Department of Radiological Sciences, Ronald Reagan UCLA Medical Center, Los Angeles, California, United States
[4]Department of Radiology, Olive View-UCLA Medical Center, Sylmar, California, United States

***Correspondence to:**
Mariam Thomas
David Geffen School of Medicine,
University of California,
Los Angeles, California, United States.

Department of Radiology,
Olive View-UCLA Medical Center,
Sylmar, California, United States.
E-mail: mathomas@dhs.lacounty.gov

Received: May 15, 2024
Accepted: July 01, 2024
Published: July 12, 2024

Citation: Kim JS, Eng IK, Yee JM, Lee M, Deshmukh M, et al. 2024. A Rare Case of Mature Cystic Teratoma with Infantile Hemangioma and Pericardial Invasion. *J Med Imaging Case Rep* 8(1): 14-17.

Copyright: © 2024 Kim et al. This is an Open Access article distributed under the terms of the Creative Commons Attribution 4.0 International License (CCBY) (http://creativecommons.org/licenses/by/4.0/) which permits commercial use, including reproduction, adaptation, and distribution of the article provided the original author and source are credited.

Published by United Scientific Group

Abstract

Distinguishing the origin of mediastinal masses as pericardial or paracardial is difficult and has significant implications for subsequent treatment. We present the first reported case of a mature cystic teratoma with infantile hemangioma that initially appeared to be a paracardial mass abutting the pericardium but was found to be a paracardial mass with pericardial invasion. Although computed tomography (CT) and magnetic resonance imaging (MRI) are the diagnostic modalities of choice to localize and assess infiltrative growth into surrounding structures, imaging may not fully capture the underlying pathology as in our case.

Keywords

Chest pain, Computed tomography, Cardiac magnetic resonance, Positron emission tomography

Abbreviations

GCT = Germ cell tumor; CXR = Chest x-ray; PET/CT = Positron emission tomography/Computed tomography; MRI = Magnetic resonance imaging; GLUT-1 = Glucose transporter 1; STIR = Short tau inversion recovery

Introduction

Mature cystic teratomas are rare germ cell tumors (GCT) comprised of well-differentiated derivatives of ectodermal, mesodermal, and endodermal germinal layers. They are slow growing and benign, accounting for approximately 7-11% of mediastinal masses and most commonly seen in 20 - 40 years old adults [1, 2]. Although the majority of patients with mature cystic teratoma are asymptomatic, they may develop symptoms such as chest pain, dyspnea, cough, and respiratory distress due to compression of surrounding structures [3]. Here, we present the first reported case of mature cystic teratoma with infantile hemangioma.

Case Presentation

A 19-year-old woman presented to an outside hospital emergency department for right anterior chest pain with radiation to the right back. The patient was a healthy adult with past medical history only notable for one year of daily vaping, although she discontinued at the onset of symptoms. She denied dyspnea, cough, fevers, or recent illness, and extensive work up was deferred. When she presented again with the same symptoms two weeks later, she was referred to pulmonology and underwent additional imaging, which revealed an ovoid right cardiophrenic

mass. The patient presented to our institution for further management.

An ovoid right cardiophrenic was also seen on a CXR obtained at our institution (Figure 1A). PET/CT showed predominantly cystic mass in the right mediastinum as well as adjacent pleural thickening regions with hypermetabolic activity both in the mass and pleura (Figure 2). Chest MRI was subsequently obtained for further characterization. It demonstrated 7.1 cm x 6.2 cm right paracardiac heterogeneously enhancing soft tissue mass with fat, hemorrhagic fluid, proteinaceous fluid, and soft tissue intensities with possible invasion to right middle lobe with evidence of lobulated nodules but without invasion to pericardium, parietal pleura, or diaphragm (Figure 3). Due to concern for GCT, which may require neoadjuvant chemotherapy prior to surgical resection, serum tumor markers including alpha fetoprotein, beta human chorionic gonadotropin, and lactate dehydrogenase were evaluated. All tumor markers were negative.

Subsequently, CT-guided core needle biopsy was performed for tissue diagnosis, which revealed fibrous tissue with mild focal chronic inflammation without features diagnostic of malignancy. However, due to continued high suspicion for GCT and high margin of error associated with needle biopsies, repeat CT-guided core needle biopsy was performed a week later. Pathology at the time revealed skin, cutaneous adnexal structures, and keratin debris consistent with mature teratoma, and the patient was diagnosed with a mature cystic teratoma abutting the pericardium.

The patient underwent video-assisted thoracoscopic surgery with planned conversion to right anterolateral thoracotomy for resection of the mature cystic teratoma. In contrast to pre-operative imaging, the mass was found to be invading the pericardium as well as the thymus, right hemidiaphragm, and right lower lobe lung parenchyma intra-operatively. A wide pericardial resection was performed, and multiple pericardial margins were sent for pathological evaluation, which were negative for malignancy. The pericardium was subsequently reconstructed with Gore-Tex pericardial patch. Due to extent

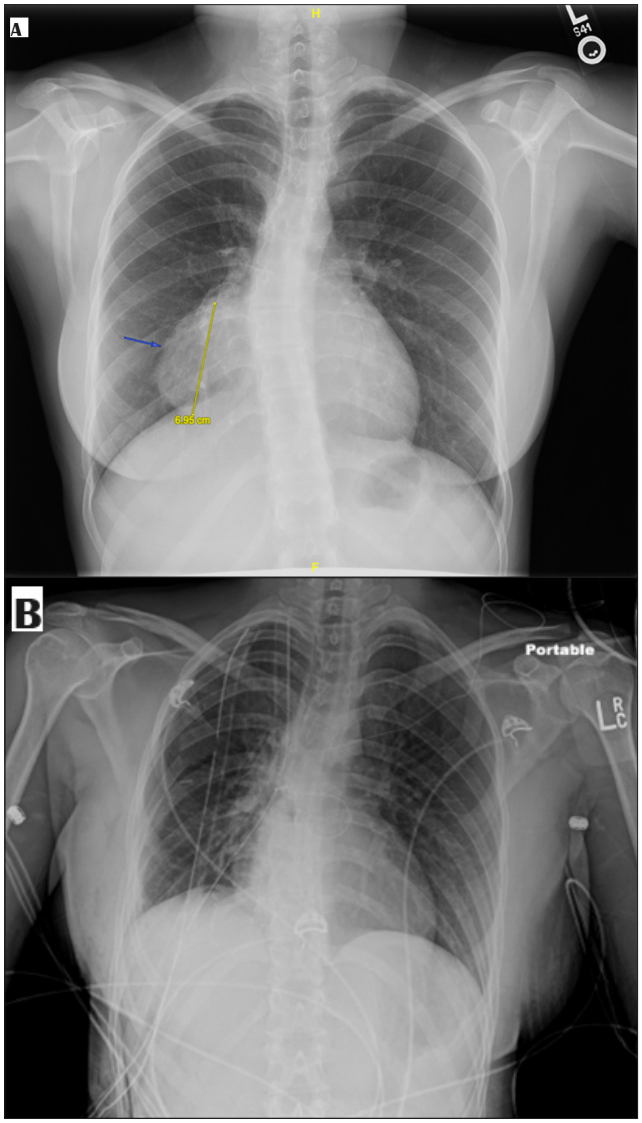

Figure 1: Chest radiograph. **(A)** Pre-operative anteroposterior CXR. and **(B)** Post-operative antero-posterior CXR.

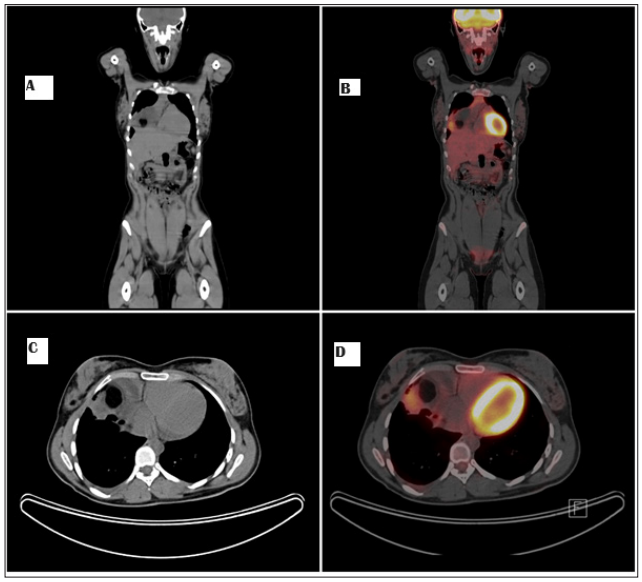

Figure 2: PET/CT. **(A)** Coronal CT. **(B)** Coronal PET. **(C)** Axial CT. and **(D)** Axial PET.

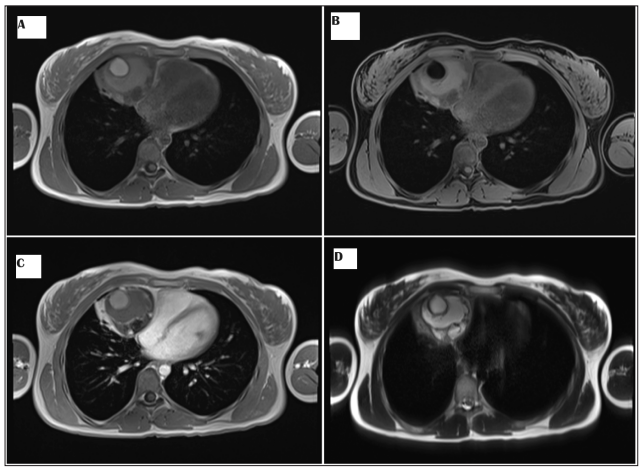

Figure 3: Axial chest MRI. **(A)** Pre-contrast T1 image without fat saturation. **(B)** Pre-contrast T1 image with fat saturation. **(C)** Post-contrast T1 image without fat saturation. and **(D)** T2 image.

of the teratoma, partial thymectomy, partial right hemidiaphragm resection, and right lower lobe wedge resection was also performed. The excised 6.3 cm mature cystic mediastinal teratoma was histologically found to contain an area of capillary proliferation with features of infantile hemangioma with reactivity for glucose transporter 1 (GLUT-1) associated with intestinal-type epithelial elements.

Post-operative chest radiograph was without evidence of pneumothorax (Figure 1B). The patient was placed on metoprolol for atrial fibrillation prophylaxis alongside adequate pain control. On post-operative day one, she developed right-sided chest pain with tachycardia, elevated troponin, and echocardiogram revealing mild ST elevation suggestive of pericarditis. She was started on colchicine, which resolved her symptoms. On post-operative day five, the patient was discharged home in a stable condition. One-and-a-half years after surgery, the patient remains free of symptoms and without evidence of disease on CT (Figure 4).

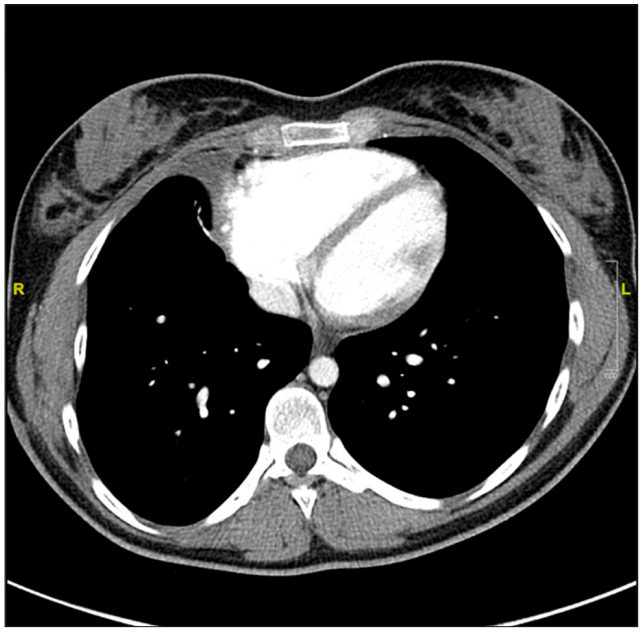

Figure 4: Follow-up CT chest with contrast. Axial CT chest with contrast 1.5 years after surgical resection.

Discussion

We present the first reported case of mature cystic teratoma composed of infantile hemangioma with reactivity to intestinal-type epithelial GLUT-1. While endothelial GLUT-1 has been historically shown to have specific immunoreactivity in infantile hemangiomas, our case describes an epithelial GLUT-1 within the teratoma [4]. Although these characteristics have unclear significance pertaining to clinical outcome, epithelial elements combined with inherently endothelial hemangioma is consistent with teratoma being a mixture of the three germinal layers.

Diagnosis of mature cystic teratoma, as with other mediastinal masses, is initially dependent on imaging with CXR, CT, and MRI. CXR is useful in narrowing the differential diagnosis of a mediastinal mass according to the anatomical compartments, particularly if lateral radiographs are also obtained. A typical appearance on CT is a heterogeneous, lobulated, thick-walled cystic mass containing soft tissue, fluid, fat, and calcium attenuation, as well as any mixture of the four [5]. MRI is useful in reliably differentiating cystic from solid lesions, as cysts are identified as homogeneous hyperintensity on T2-weighted sequences due to fluid and variable intensity on T1-weighted sequences (hypointensity for serous fluid, hyperintensity for proteinaceous fluid and hemorrhage) [6]. MRI can also be used to evaluate mass infiltration of adjacent structures by fat plane obliteration, as intra-teratoma fat appears hyperintense on T1-weighted sequence and hypointense on T1-weighted fat saturated sequence [1, 6]. However, this relies on the assumption that the mature teratoma contains components of macroscopic and/or microscopic fat.

We propose that in the setting of continued diagnostic uncertainty with negative tissue biopsy, as in our case, re-biopsy should be pursued if clinical suspicion for GCT remains high, not only to establish a tissue diagnosis but to guide treatment. While immature teratomas are treated with neoadjuvant therapy, mature teratomas are immediately resected surgically given relative insensitivity to both chemotherapy and radiation therapy. Complete resection is almost always curative, and subtotal excision is limited to cases in which complete resection would endanger surrounding structures.

The diagnostic challenge was in distinguishing the origin of the right mediastinal mass as arising from the pericardium or not. We initially suspected a pericardial mass given pericardial teratomas are usually right sided, while mediastinal teratomas have a tendency towards the left and posterior compartments [3, 7]. However, subsequent higher resolution imaging suggested paracardial mass without infiltration into the pericardium. Correct identification of the mass location is particularly important as pericardial mass requires more urgent intervention given increased susceptibility to hemodynamic compromise from pericardial effusion or cardiac tamponade as well as life-threatening arrhythmias [3].

While a pre-operative diagnosis of paracardial mature cystic teratoma was made, we found extensive infiltration into the pericardium intra-operatively. This case thus serves as a cautionary reminder that paracardial and pericardial differentiation of mediastinal mass remains difficult, and the lack of apparent pericardial invasion on imaging does not definitively rule out the possibility. Although rare, it is thus important to consider mature cystic teratoma as part of the differential diagnosis for both paracardial and pericardial mass.

Learning objectives

Case: A patient who presented with mature cystic teratoma with infantile hemangioma

1. To make a differential diagnosis of paracardial/pericardial mass.
2. To understand natural history and management of mature cystic teratoma.

Acknowledgements

None.

Conflicts of Interest

None.

References

1. Duc VT, Thuy TT, Bang HT, Vy TT. 2020. Imaging findings of three cases of large mediastinal mature cystic teratoma. *Radiol Case Rep* 15(7): 1058-1065. https://doi.org/10.1016/j.radcr.2020.05.011
2. Ahmed A, Lotfollahzadeh S. 2023. Cystic Teratoma. In StatPearls. Treasure Island (FL): StatPearls Publishing.
3. Cohen RA, Loarte P, Navarro V, Mirrer B. 2012. Mature cardiac teratoma in an adult. *Cardiol Res* 3(3): 97-99. https://doi.org/10.4021/cr182w
4. Ford JR, Gonzalez-Barlatay J, Valenzuela AA. 2018. Early orbital infantile hemangioma that emphasizes the importance of glucose-transporter-1 (GLUT-1). *Can J Ophthalmol* 53(2): e58-e60. https://doi.org/10.1016/j.jcjo.2017.07.003
5. Moeller KH, Rosado-de-Christenson ML, Templeton PA. 1997. Mediastinal mature teratoma: imaging features. *AJR Am Roentgenol* 169(4): 985-990. https://doi.org/10.2214/ajr.169.4.9308448
6. Carter BW, Betancourt SL, Benveniste MF. 2017. MR imaging of mediastinal masses. *Top Magn Reson Imaging* 26(4): 153-165. https://doi.org/10.1097/rmr.0000000000000134
7. Rüffer A, Webinger J, Glöckler M, Purbojo A, Dittrich S, et al. 2012. Pericardial cyst or teratoma? Change of strategy during mediastinal tumor surgery. *Thoracic Cardiovasc Surg* 60(7): 488-490. https://doi.org/10.1055/s-0031-1280065