Journal of Medical Imaging & Case Reports

https://doi.org/10.17756/micr.2024-106

Case Report

Open Access

Case Report of Antiphospholipid Syndrome Complicated with Adrenal Infarction

Alluri Vignatha[1*], Divya Viraajitha Vurutha[2], Shrilekha[3], Ramireddy Sulekha[4] and Arya Raveendran[5]

[1]*RVM Institute of Medical Sciences and Research Center, Siddipet, Telangana, India*
[2]*NRI Institute of Medical Sciences, Vishakapatnam, Andhra Pradesh, India*
[3]*Kilpauk Medical College, Chennai, Tamil Nadu, India*
[4]*Malla Reddy Institute of Medical Sciences, Hyderabad, Telangana, India*
[5]*Angeles University Foundation, Angeles, Philippines*

***Correspondence to:**
Alluri Vignatha
RVM Institute of Medical Sciences and Research Center,
Siddipet, Telangana, India.

Received: June 03, 2024
Accepted: August 19, 2024
Published: August 23, 2024

Citation: Vignatha A, Vurutha VD, Shrilekha, Sulekha R, Raveendran A. 2024. Case Report of Antiphospholipid Syndrome Complicated with Adrenal Infarction. *J Med Imaging Case Rep* 8(1): 23-27.

Copyright: © 2024 Vignatha et al. This is an Open Access article distributed under the terms of the Creative Commons Attribution 4.0 International License (CCBY) (http://creativecommons.org/licenses/by/4.0/) which permits commercial use, including reproduction, adaptation, and distribution of the article provided the original author and source are credited.

Published by United Scientific Group

Abstract

Antiphospholipid syndrome (APS) involves multiple organ systems in the body with endocrine involvement being a rare manifestation. The first endocrine manifestation of APS is adrenal insufficiency (AI) in the majority of the cases. AI being a fatal condition needs prompt diagnosis to avoid life threatening condition. Diagnosis of APS needs a combination of clinical features and laboratory investigations, whereas AI needs a low early morning serum cortisol level along with an elevated adrenocorticotropic hormone (ACTH). Here we present a case of a 36-year-old female who had multiple vascular complications of APS in the form of fetal losses, deep vein thrombosis, cerebrovascular accident, and AI due to adrenal infarct. Due to its rarity and nonspecific presentation, every case of adrenal hemorrhage (AH) and infarction with no known etiology should be evaluated for APS and screened with lupus anticoagulant, anti-beta 2 microglobulin and anti-cardiolipin antibodies.

Keywords

Antiphospholipid syndrome, Adrenal insufficiency, Ischemic stroke, Autoimmune hepatitis, Thrombophilia

Introduction

APS is an autoimmune disease characterized by acquired thrombophilia, recurrent thrombosis, and pregnancy morbidity. These symptoms are associated with a diverse group of antibodies known as antiphospholipid antibodies. APS can impact multiple organs, although endocrine symptoms are infrequent. AI is a less common manifestation of APS [1]. Adrenal gland hemorrhagic infarction can be caused by stress factors such as surgery, sickness, or anticoagulant therapy [2]. APS has the potential to induce infrequent and life-threatening primary AI. Primary AI can occur as a result of thrombosis caused by coagulopathy, which can progress to hemorrhagic infarction [3]. Adrenal function can be impaired by the rapid occurrence of thrombosis and bleeding in the adrenal cortex. This study examines existing research to provide guidance for future treatment. This has the potential to be lethal. Therefore, it is crucial to diagnose AH early and administer steroid replacement therapy. Adrenal vein thrombosis can cause hemorrhagic infarction by obstructing the outflow of the adrenal gland. Tissue necrosis may occur if an adrenal gland vein is obstructed by a blood clot, often known as thrombosis. Choosing the optimal anticoagulant drug for people with APS who experience severe blood clotting can be challenging. New pharmacological anticoagulants are being discovered as science progresses. Ongoing research is being conducted to thoroughly examine their efficacy and safety. Failure to address AI can have

fatal consequences, hence it is imperative to recognize this issue. A systematic study found that the death rate in patients with systemic lupus erythematosus (SLE) and APS combined with autoimmune hepatitis was 3.81%, which is relatively high considering the young age of the patients [4]. Despite previous reporting, physicians continue to be perplexed by this clinical condition due to its unassuming appearance.

Case Report

The primary complaint of a 36-year-old housewife who works as a housekeeper and lives in Govindpur village, Medak district, was a chronic non healing ulcer with swelling. When her medical history was obtained, she disclosed that she was taking medicine for repeated episodes of deep vein thrombosis. She gave birth to a deceased female baby spontaneously via vaginal delivery (Gravida 1) when she was 18-years-old in 2006. Her vital signs were normal at the time of the delivery, including LFT, CUE, and a normal haemogram (platelets: 1,99,000).

Later in 2007 (Gravida 2), she gave birth to a female baby via vaginal delivery at full term. In 2008 patient had placenta previa (Gravida 3). She underwent a self-induced medical termination of pregnancy in 2009 (Gravida 4). In the year 2010 a patient developed Bell's palsy, for which she was prescribed Tab. Ecospirin and Tab. Wysolone 5 mg as steroids. She experienced a spontaneous vaginal delivery (Gravida 5) at 36 weeks in 2010 and suffered from severe pre-eclampsia and had intrauterine death. She first complained of pain and swelling in her right lower limb in 2012 for which the Doppler study was conducted which showed a right lower limb deep venous thrombosis that extended from the right popliteal vein to the right external iliac vein. A few months later, she had inferior vena cava (IVC) filters installed and was receiving follow-up treatments with Ecospirin AV 150/20 OD and Acitrom 2 mg OD. She complained of pain and swelling in her left lower limb in 2019 and was diagnosed with deep vein thrombosis in the left leg. and began taking 15 mg Tab. Xarelto OD.

After experiencing abdominal pain for a month, she was diagnosed with right hydroureteronephrosis. One month later, patient experienced menorrhagia for 20 days afterward. After experiencing seizures a few days later, an ischemic stroke (CVA) with a right middle cerebral artery region infarct was identified during the investigation. She complained of abdominal pain as her main complaint a year later. An abdomen CT scan was performed. A 3.5 × 2.4 cm right adrenal incidentaloma-a non-functional adrenal mass was found (Figure 1).

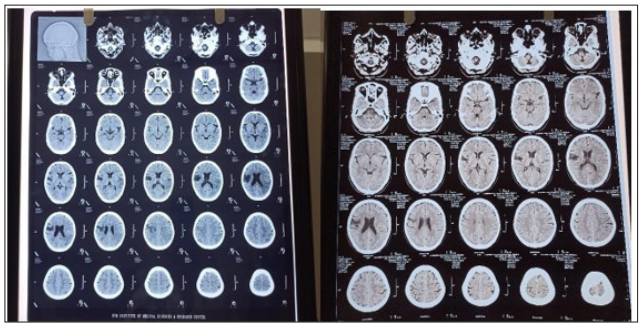

Figure 1: CT scan.

After a positron emission tomography (PET) scan, the results indicated a left-sided ovarian cyst and a very well-defined non-enhancing soft tissue density lesion involving the right adrenal gland with no tracer uptake. Left ovarian cyst was examined histopathologically, a sizable hemorrhagic corpus luteal cyst without any indication of cancer was found. Histopathological examination of the adrenal gland's showed marked infarction, hemorrhage with thrombus, and fat necrosis with giant cell reaction in the periadrenal soft tissue (Figure 2).

The intraoperative results were:

- Right adrenal adenoma haemorrhage into lesion of size 6-by-5-cm.
- Densely adherent lesion to IVC.
- A 6 x 6 cm ovarian cyst on the left with hemorrhage.

After two years (2022), she experienced a persistent, non-healing ulcer on her left foot and right thigh, for which debridement was done. She returned four months later with a chronic, non-healing ulcer over her left foot and right thigh, for which she received symptomatic treatment. She was later diagnosed with anemia and non-erosive gastritis that year. Her main concerns one year later (2023) were excessive monthly bleeding, urinary incontinence, and ulcers over vulva. After a complete abdominal CT scan, a complicated multiloculated right ovarian cyst was suggested.

In July 2023 patient was diagnosed with primary AI after the patient presented with adrenal crisis and she was put on:

- Tab. Wysolone 5 mg H/S
- Floricot 100 µg H/S

She went to RVM Hospital in September 2023 with a left thigh abscess and septicemia. The diagnosis of antiphospholipid antibody syndrome (APLS), came after a series of investigations. She was admitted in 2024 with a suspected case



Figure 2: PET scan.

of chronic renal disease. She experienced hyponatremia and hypoglycemia as a result of an adrenal crisis a few months later. She recently displayed bullous lesions.

Discussion

APS is a medical condition that is distinguished by the formation of blood clots in the vascular system of both the arteries and vessels. It may manifest as either a primary disorder or as a subsequent complication of other systemic autoimmune conditions, such as SLE. A documented history of previous blood coagulation episodes, as well as the detection of antiphospholipid antibodies in the blood serum on two or more separate occasions with a minimum of 12 weeks between each occurrence, are used to confirm the diagnosis. The clinical manifestations of APS are extensive and have the potential to affect nearly every organ system in the body. The following are endocrine symptoms of APS: Autoimmune thyroid disease, AI, hypopituitarism, diabetes mellitus, and thrombosis of the ovarian and testicular vascular routes.

Primary AI is characterized by a deficiency in the production of essential glucocorticoids and mineralocorticoids as a result of injury to the adrenal cortex. Autoimmune adrenalitis is believed to be the predominant cause of primary AI in Western countries, accounting for 70 to 90% of cases. Other potential causes of the condition include metastatic cancer, lymphoma, certain medications, or tuberculosis (7 to 20% of cases). In only 5% of cases, AI is a result of APS [5].

Although there are some potential explanations, the precise pathophysiologic mechanisms that induce AI in APS have not yet been definitively identified. The adrenal glands are supplied with a plentiful blood supply by the arteries; however, they are discharged by a single adrenal vein [5, 6]. Hemorrhagic infarction is the primary cause of hypoadrenalism, and it is more likely to occur as a result of the thrombosis of the restricted blood flow through the vessels [7]. The predominant pathology in adrenal vein thrombosis is caused by the unique vascular structure of the adrenal gland. The adrenal gland is adequately supplied with blood vessels, which include three primary arteries and a solitary vein. A vascular plexus is formed around the zona reticularis by the capillaries that originate from the adrenal arteries. The term "vascular dam" denotes the abrupt transition from the network of arteries to the network of capillaries, which is characterized by thrombosis, infarction, and subsequent hemorrhage as a result of the combined effect of venous stasis and hypercoagulability in this region. In addition, the vein's musculature is composed of longitudinal muscle bundles that are densely packed and arranged in an eccentric manner. This promotes the formation of blood clots in quiescent regions that result from their constriction. The zona reticularis is significantly impaired in comparison to the zona glomerulosa and fasciculata due to its location in a more remote area from the vascular obstruction. At the conclusion, the capillary plexus, a network of small blood vessels, drains into the medullary sinusoids, which subsequently unite to create a single central vein.

Additionally, a novel mechanism has been suggested that is related to the cellular properties of zona fasciculata. Late endosomes, which are organelles that are responsible for cholesterol exchange and protein sorting, are present in high concentrations within the cells of this region. In the membranes of these organelles, lysobiphosphatidic acid is present, and antiphospholipid antibodies are designed to target these products. Antiphospholipid bodies induce a localized reaction that results in the accumulation of cholesterol within the cell, which in turn induces cell death and the release of lysosomal proteinases. Consequently, this mechanism enhances coagulation and results in the formation of micro-thrombosis by stimulating endothelial cells. The anatomical symmetry and comparable histologic features of adrenal glands account for the symmetrical pattern associated with AH. Furthermore, anticoagulation and heparin-induced thrombocytopenia can also result in bilateral AH.

Generally, the symptoms of AH caused by APS are nonspecific, including lethargy, weakness, fatigue, and a disturbed mental state. However, the diagnosis of AI should be initiated by the presence of low blood pressure and abdominal discomfort on both sides. In a study published by Arberas et al. [8] it was discovered that abdominal distress was restricted to the pericardial, epigastric, lumbar, and umbilical regions in 66% of cases. Fever was present in 50% of cases, either intermittently or continuously, while 12% of cases exhibited altered mental status, lethargy, and asthenia. In 19% of the cases, low blood pressure was observed. Arberas et al [8] conducted a case series that included 86 patients. Abdominal pain was reported by 55% of these patients, hypotension was experienced by 54%, and fever was experienced by 40%. On the other hand, the remaining patients demonstrated lethargy or altered mental status (19%), weakness or fatigue (31%), and nausea or vomiting (31%). Espinosa et al. [9] discovered that 40% of the 86 patients with APS syndrome and AI experienced deep venous thrombosis in their extremities, 17% had pulmonary embolism, and 19% had arterial occlusion in their study [9].

Hemorrhagic infarction was the most prevalent symptom in APLS patients with AI, despite the fact that APLS is distinguished by elevated blood coagulation. Vessel thrombosis was identified in 55% of patients through biopsy (autopsy was performed in 16 patients). In 27% of patients, AH is present, adrenal infarction in 5%, and 9% of patients have a normal appearance. These results corroborate the hypothesis that adrenal vein thrombosis is the primary cause of the majority of PAI cases in APLS, with hemorrhagic transformation following. AI is present in 0.4% of individuals with APLS [9]. In a cohort of 69 patients with adrenal involvement in APLS who underwent CT and/or MRI, 57% were diagnosed with AH, 10% with adrenal infarction, and 10% with adrenal hypertrophy. 77% of the individuals reported bilateral adrenal involvement [3]. Using CT imaging, the diagnosis of AH was identified in our case. The imaging revealed adrenal congestion and signs of a moderate hemorrhage. The development of diffuse gland hypertrophy and adrenal enlargement has been identified as a predisposing factor to AH [10, 11].

In the event of any clinical signs of acute AI, it is imperative to promptly assess cortisol and ACTH levels, and a strong suspicion is necessary. The diagnosis of AI can be further es-

tablished through supplementary laboratory testing, including dehydroepiandrosterone sulfate, aldosterone, and renin activity. The diagnosis of primary AI is made when the response to 250 μg of ACTH is weakened, despite the fact that the ACTH levels were elevated at the beginning. However, the diagnosis of AI is sufficient when a decreased blood cortisol level is accompanied by an elevated ACTH level. When there are elevated levels of antibodies, including lupus anticoagulant, anticardiolipin antibodies, and/or anti-β2-glycoprotein antibodies, without any clinical signs of other rheumatologic disorders, such as SLE, APS is definitively diagnosed [9]. AH is the primary finding in adrenal gland imaging (59%), while hemorrhagic infarction accompanied by vascular thrombosis is the predominant finding in a histopathologic examination [11]. In the past, the majority of bilateral AH were only discovered after the patient's mortality due to the fact that the symptoms were not readily apparent. The abdominal CT scan is the preferred method for observing the adrenal glands and can assist in the early diagnosis of the illness. A CT scan may not detect any abnormalities during the initial stages of the disease. Nevertheless, it is advisable to repeat the CT scan in order to detect any structural alterations if symptoms persist [12]. The purpose of measuring catecholamines is not well understood in the current situation. Nevertheless, it is clear that the production of epinephrine is the most perceptible, as it is released from the medulla and is dependent on cortisol generated within the adrenal gland for its production. The efficacy of norepinephrine may be diminished as a result of its ability to induce the production of adrenaline.

It is only logical to postulate that warfarin may have a lower risk of AH than direct oral anticoagulants (DOACs) due to the limited availability of case data. In addition, there have been reports that individuals with APS developed CAPS after transitioning from warfarin to DOACs [13]. It is imperative to underscore that each of them exhibited triple-positive APS. Individuals who were not diagnosed with APS and were receiving DOACs also experienced AH [14, 15].

At present, there is conflicting information regarding the use of DOACs for the secondary prevention of thrombotic events in patients with APLS [16]. The patient's APLS antibody status can be used to classify the probability of thrombosis associated with the administration of DOACs. In a recent retrospective analysis, the incidence of venous thromboembolism or bleeding events between single-positive APLS patients who are treated with DOAC (apixaban or rivaroxaban) and those who are treated with warfarin is not significantly different [17]. EULAR advises against the use of DOACs in patients with triple-positive APS [18]. The established anticoagulant of choice should continue to be warfarin until additional evidence regarding the safety of DOACs in APLS is available.

When AH occurs, there is a dearth of information regarding the recovery process of the adrenal glands, particularly when there is evidence of partial preservation of function, preserved aldosterone, and moderate deficiencies in cortisol, adrenal androgens, and potentially catecholamines. Consequently, it is advisable to establish a strong rapport with the patient, provide empirical steroid replacement treatment, and conduct regular evaluations of the HPA axis. Additionally, it is prudent to encourage the reporting of long-term outcomes in order to obtain prognostic data.

Treatment for patients diagnosed with AI should commence immediately with stress doses of hydrocortisone, which should be gradually increased to a suitable replacement dosage once their condition has returned to normal. If aldosterone deficiency is confirmed, fludrocortisone may be administered as an alternative to mineralocorticoids. The management of thrombosis in patients with APS is a topic of controversy due to its documented association with thrombophilia and the increased risk of bleeding associated with continuous anticoagulant therapy. Anticoagulation is the primary therapeutic approach for patients with bilateral AH and APS, despite its paradoxical nature. This therapy provides the enduring advantage of preventing subsequent thrombotic events [19].

Subsequent evaluations are essential for these patients to ascertain their long-term adrenal function. Ramon et al. [20] conducted a retrospective study to examine the long-term outcomes of 16 individuals who underwent bilateral AH-adrenal infarction as a consequence of APS. Individuals who survived the initial stage of adrenal involvement in this investigation exhibited a relatively optimistic outlook. The investigation monitored these patients for a median of 3.5 years. Furthermore, research indicates that adrenal dysfunction may undergo partial recovery in isolated cases; however, it is generally irreversible. Testing the levels of cortisol in the early morning serum during follow-up is recommended to identify patients who may have experienced spontaneous adrenal axis recovery [20]. In a study conducted by Jahangir-Hekmat et al. [21], four patients had acute bilateral AH and AI. The patients were monitored for a period of 6 to 19 years. Three of the patients underwent partial recovery, while one patient attained complete recovery. Ramon et al. [20] conducted a retrospective analysis on individuals who experienced bilateral AH-adrenal infarction as a consequence of APS between 1990 and 2010. The researchers concluded that adrenal dysfunction is typically permanent, although there is a potential for partial improvement [20].

Conclusion

High degree of suspicion is needed from a physician when a patient presents with non-specific complaints like abdominal pain, weakness, malaise and asthenia to diagnose AI. Laboratory confirmation of serum cortisol, serum ACTH, Serum electrolytes and blood pressure monitoring should be done to confirm the diagnosis of AI. At the same time patients presenting with AI from an unknown etiology should be promptly evaluated for the diagnosis of APS. Patients who are diagnosed with adrenal infarction and haemorrhage should be actively screened for lupus anticoagulant, anti-β 2 microglobulin and anticardiolipin antibodies. AI being in a high mortality condition needs high clinical suspicion and prompt diagnosis for the proper timely management.

Acknowledgments

None.

Conflicts of Interest

None.

References

1. Uthman I, Salti I, Khamashta M. 2006. Endocrinologic manifestations of the antiphospholipid syndrome. *Lupus* 15(8): 485-489. https://doi.org/10.1191/0961203306lu2318rr
2. Caron P, Chabannier MH, Cambus JP, Fortenfant F, Otal P, et al. 1998. Definitive adrenal insufficiency due to bilateral adrenal hemorrhage and primary antiphospholipid syndrome. *J Clin Endocrinol Metab* 83(5): 1437-1439. https://doi.org/10.1210/jcem.83.5.4833
3. Elshimy G, Alghoula F, Jeong JM. 2020. Adrenal Crisis: 2019 Aug 22. StatPearls Publishing.
4. Lee KH, Lee H, Lee CH, Kim JY, Kim JM, et al. 2019. Adrenal insufficiency in systematic lupus erythematosus (SLE) and antiphospholipid syndrome (APS): a systematic review. *Autoimmun Rev* 18(1): 1-8. https://doi.org/10.1016/j.autrev.2018.06.014
5. Presotto F, Fornasini F, Betterle C, Federspil G, Rossato M. 2005. Acute adrenal failure as the heralding symptom of primary antiphospholipid syndrome: report of a case and review of the literature. *Eur J Endocrinol* 153(4): 507-514. https://doi.org/10.1530/eje.1.02002
6. Zelissen PM, Bast EJ, Croughs RJ. 1995. Associated autoimmunity in Addison's disease. *J Autoimmun* 8(1): 121-130. https://doi.org/10.1006/jaut.1995.0009
7. Anson BJ, Cauldwell EW. 1947. The blood supply of the kidney, suprarenal gland, and associated structures. *Surg Gynecol Obstet* 84(3): 313-320.
8. Arberas E. 2002. Acute adrenal insufficiency caused by bilateral adrenal hemorrhage as first manifestation of antiphospholipid syndrome. Report of a case and review. *Ann Med Intern* 19(1): 19-22.
9. Espinosa G, Santos E, Cervera R, Piette JC, de la Red G, et al. (2003) Adrenal involvement in the antiphospholipid syndrome: clinical and immunologic characteristics of 86 patients. *Medicine* 82(2): 106-118. https://doi.org/10.1097/00005792-200303000-00005
10. Di Serafino M, Severino R, Coppola V, Gioioso M, Rocca R, et al. 2017. Nontraumatic adrenal hemorrhage: the adrenal stress. *Radiol Case Rep* 12(3): 483-487. https://doi.org/10.1016%2Fj.radcr.2017.03.020
11. Tan GX, Sutherland T. 2016. Adrenal congestion preceding adrenal hemorrhage on CT imaging: a case series. *Abdom Radiol* 41(2): 303-310. https://doi.org/10.1007/s00261-015-0575-9
12. Vella A, Nippoldt TB, Morris III JC. 2001. Adrenal hemorrhage: a 25-year experience at the Mayo clinic. *Mayo Clinic Proceedings* 76(2): 161-168. https://doi.org/10.4065/76.2.161
13. Stammler R, Legendre P, Cacoub P, Blanche P, Piette JC, et al. 2020. Catastrophic antiphospholipid syndrome following the introduction of rivaroxaban. *Lupus* 29(7): 787-790. https://doi.org/10.1177/0961203320914363
14. Alidoost M, Soomro R, Gubeladze A, Morabia A, Holland S, et al. 2019. Rivaroxaban related bilateral adrenal hemorrhage: a rare complications of direct oral anticoagulants–a case reports. *Am J Case Rep* 20: 1607. https://doi.org/10.12659%2FAJCR.917780
15. Zampetti B, Attanasio R, Cozzi R. 2018. Hyponatremia after anticoagulant treatment: a rare cause of adrenal failure. *Endocrinol Diabetes Metab Case Rep* 2018(1): 1-3. https://doi.org/10.1530%2FEDM-18-0101
16. Kakadia B, Suero-Abreu GA, Daci R, Then RK. 2020. Would you use novel oral anticoagulants (NOACs) for thromboprophylaxis in patients with an underlying hypercoagulable state? A literature review through a case report. *BMJ Case Rep* 13(10): e237238. https://doi.org/10.1136/bcr-2020-237238
17. Liu A, Rupani KV, Naymagon L. 2022. Direct oral anticoagulants versus warfarin in patients with single antibody-positive anti-phospholipid syndrome. *Eur J Haematol* 109(1): 69-74. https://doi.org/10.1111/ejh.13770
18. Tektonidou MG, Andreoli L, Limper M, Amoura Z, Cervera R, et al. 2019. EULAR recommendations for the management of antiphospholipid syndrome in adults. *Ann Rheum Dis* 78(10): 1296-1304. https://doi.org/10.1136/annrheumdis-2019-215213
19. Ruiz-Irastorza G, Cuadrado MJ, Ruiz-Arruza I, Brey R, Crowther M, et al. 2011. Evidence-based recommendations for the prevention and long-term management of thrombosis in antiphospholipid antibody-positive patients: report of a task force at the 13th International Congress on antiphospholipid antibodies. *Lupus* 20(2): 206-218. https://doi.org/10.1177/0961203310395803
20. Ramon I, Mathian A, Bachelot A, Hervier B, Haroche J, et al. 2013. Primary adrenal insufficiency due to bilateral adrenal hemorrhage-adrenal infarction in the antiphospholipid syndrome: long-term outcome of 16 patients. *J Clin Endocrinol Metabol* 98(8): 3179-3189. https://doi.org/10.1210/jc.2012-4300
21. Jahangir-Hekmat M, Taylor HC, Levin H, Wilbur M, Llerena LA. 2004. Adrenal insufficiency attributable to adrenal hemorrhage: long-term follow-up with reference to glucocorticoid and mineralocorticoid function and replacement. *Endocr Pract* 10(1): 55-61. https://doi.org/10.4158/EP.10.1.55