Journal of Medical Imaging & Case Reports

https://doi.org/10.17756/micr.2025-112

Case Series

Open Access

Case Series and Literature Review of Rare Intracranial Presentations of Classic Hodgkin Lymphoma

Karan Bir Singh[1], Krithika Muthyala[2], Daniel Pierotti[3], Brett Martin[4], Esther Morrison[5], Matthew Pearson[6] and Omar Alkharabsheh[7*]

[1]*Department of Vascular and Interventional Radiology, SSM Health Saint Louis University, Saint Louis, Missouri, United States*
[2]*Department of Internal Medicine, University of South Alabama, Alabama, United States*
[3]*Department of Neurology, University of South Alabama, Alabama, United States*
[4]*Department of Radiology, University of South Alabama, Alabama, United States*
[5] *Department of Infectious Disease, University of South Alabama, Alabama, United States*
[6]*Department of Neurosurgery, University of South Alabama, Alabama, United States*
[7]*Division of Medical Oncology, Mitchell Cancer Institute, University of South Alabama, Alabama, United States*

***Correspondence to:**
Omar Alkharabsheh
Division of Medical Oncology,
Mitchell Cancer Institute,
University of South Alabama,
Alabama, United States.

E-mail: oalkharabsheh@health.southalabama.edu

Received: January 03, 2025
Accepted: February 17, 2025
Published: February 21, 2025

Citation: Singh KB, Muthyala K, Pierotti D, Martin B, Morrison E, et al. 2025. Case Series and Literature Review of Rare Intracranial Presentations of Classic Hodgkin Lymphoma. *J Med Imaging Case Rep* 9(1): 1-6.

Copyright: © 2025 Singh et al. This is an Open Access article distributed under the terms of the Creative Commons Attribution 4.0 International License (CCBY) (http://creativecommons.org/licenses/by/4.0/) which permits commercial use, including reproduction, adaptation, and distribution of the article provided the original author and source are credited.

Published by United Scientific Group

Abstract

Classic Hodgkin lymphoma (cHL) primarily affects the lymphatic system; however, extranodal involvement occurs in approximately 10% of cases. Central nervous system (CNS) involvement, though rare, can present in various forms, including intracranial, epidural, leptomeningeal, and intramedullary spinal cord involvement. This report presents a case series of two unique cases of cHL with intracranial extra-axial extension. Case 1: 31-year-old male with Stage IVB mixed cellularity cHL presented with ataxia and weakness with intermittent fevers. Case 2: 28-year-old female with cHL presented with neck swelling and persistent lymphadenopathy. Both were treated with both novel combination and conventional chemotherapy regimens. Treatment with Adcetris-Adriamycin, Vinblastine, Dacarbazine (A-AVD) has demonstrated superior efficacy compared to traditional Adriamycin, Bleomycin, Vincristine, Dacarbazine (ABVD) chemotherapy. Notably, progression-free survival has been observed to be higher with nivolumab-AVD (N-AVD) compared to brentuximab-AVD (B-AVD). A literature review of intracranial Hodgkin's lymphoma (HL) case reported from 1998 to 2024 documented in various locations separated based on tissue diagnosis type, treatment type and Epstein-Barr virus (EBV) positivity documented complete remission especially with appropriate timely therapy. CNS involvement in cHL is uncommon as observed in these cases which necessitates a thorough diagnostic workup to exclude infections and other malignancies. Diagnosis relies on imaging studies followed by histopathological confirmation. Emerging therapies such as N-AVD have shown improved progression-free survival in patients with advanced-stage cHL.

Keywords

Central nervous system, Intracranial lesion, Hodgkin lymphoma, Relapse, Refractory, Neuroimaging, Ring enhancing, Immunotherapy, Chemotherapy

Introduction

HL is a malignant proliferation of B-lymphocytes within lymph nodes and classically has a high cure rate. Initiation of therapy leads to an 80% cure rate, however, 9 - 11% of patients will be refractory to first line therapy and up to 30% will have relapse following remission [1]. In 8 - 12% of cases, extra-nodal structures such as the liver and lung are involved [2]. CNS involvement of cHL is unusual and represents an immunocompromised state with higher rates in males

or predisposing infection with EBV [3]. The most common abnormality found on neuroimaging when suspecting intracranial neoplasm, is ring enhancement [4]. These lesions are hypodense on non-contrast computed tomography (NCCT) scans or hypointense on brain magnetic resonance imaging (MRI). The most common pathologies found based on neuroimaging were gliomas (40%) followed by metastatic brain (30%) lesions [5]. Clinically this involves 70% of patients having rare focal neurological deficits, 40% with nonspecific neurocognitive behavioral changes, and 30% with intracranial hypertension [6]. Neuroimaging can presumptively diagnose the lesion; however, brain histopathology sampling is required to confirm and/or rule out other causes such as infectious versus primary cancerous. In recent years, there has been a shift towards utilizing novel agents, including antibody drug conjugates (brentuximab vedotin) and programmed death-1 (PD-1) inhibitors [7-9]. While this rare presentation limits the availability of reported cases, we hereby discuss the presentation, diagnosis and management of two intracranial extra-axial metastatic cHL.

Methodology

A case series review was conducted at the University of South Alabama Health System involving data extraction from electronic health records after obtaining IRB approval. Here in, we are describing clinical outcomes and disease characteristics with intracranial manifestations of cHL in two cases who were treated with immune checkpoint inhibitors and antibody drug conjugates.

Case Presentation

Case 1

31-year-old male with a history of untreated mycobacterium mucogenic isolated on bronchoscopy and bronchoalveolar lavage (BAL) culture 6 months prior, stage IVB mixed cellularity cHL presented to the hospital with 3-day onset of ataxia. He sustained a total of 3 falls with severe frontal headache that he rates as a 9/10 in severity. At the time of BAL, his mycobacterium infection was quiescent and BAL with flow cytometry revealed 4% lymphocytes with CD^{3+} T-cells 96%, CD^{4+} T-cells 66%, CD^{8+} T-cells 24%, CD^{56+} NK-cells 2%, CD^{19+} B-cells 0%, CD4:CD8 2.7. Subsequent lymph node biopsy favored cHL, mixed cellularity type with CD^{30+}, weakly $PAX\text{-}^{5+}$, intermediate to large, atypical cells with occasional inclusion-like nucleoli with mixed cellularity background. After diagnosis, he received 3 cycles of A-AVD regimen which he tolerated well. He denied loss of consciousness, problems with his vision, positional worsening, prior history of headaches, and neck pain. However, he reported worsening gait and generalized weakness over the course of his hospital admission. Vital signs on admission were significant: 38.2 °C, 101 beats/min, and BP 113/52 mmHg. He developed intermittent fevers as high as 39.4 °C throughout his hospital course. Physical exam revealed abnormal finger to nose and heel to shin testing with broad based magnetic gait and impaired tandem gait concerning for abnormal neurological findings. Labs revealed white blood cells (WBCs) 1.65 × $10^{(3)}$/mcL with absolute neutrophil count of 1.02 × $10^{(3)}$/mcL, alkaline phosphatase (ALP) 100 u/L, alanine aminotransferase (ALT) 75 u/L, aspartate aminotransferase (AST) 118 u/L without a clear explanation for the transaminitis. Lumbar puncture with cerebrospinal fluid (CSF) analysis did not indicate evidence of meningitis. Serology was positive for John Cunningham (JC) virus, cytomegalovirus (CMV), EBV but the CSF was negative for JC virus, CMV and herpes simplex virus (HSV). NCCT demonstrated vasogenic edema within the right temporal lobe. MRI brain with and without contrast revealed spherical 1.0 × 1.0 × 1.1 cm lesion that increased in size to 2.4 × 2.1 × 2.2 cm in 3 weeks (Figure 1 and figure 2). Patient underwent a right pteronial craniotomy with stereotactic right temporal tip dural mass biopsy by neurosurgery. Histopathology with immunoperoxidase stains performed reveal large, atypical cells positive for CD15, CD30 (partial and weak), CD79a, and PAX5. Epstein-Barr encoding region (EBER) in-situ hybridization study lacked evidence of EBV. He was initiated on a dexamethasone taper over 5 days and salvage therapy with DHAP as inpatient and eventually immunotherapy with pembrolizumab with gemcitabine, vinorelbine, and liposomal doxorubicin (pembro-GVD) as outpatient. Repeat positron emission tomography (PET) CT scan demonstrated positive response and MRI of brain

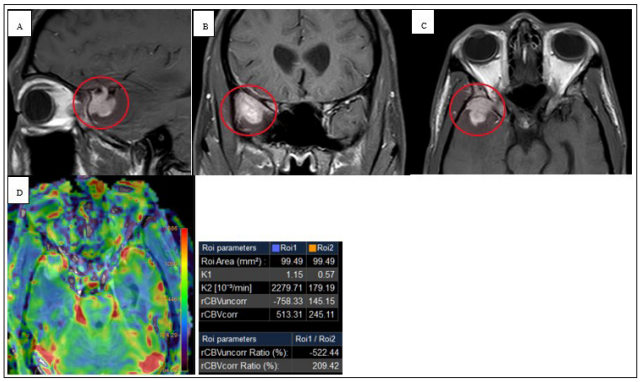

Figure 1: (A) Pretreatment sagittal T1, (B) coronal T1, (C) axial T1 post-contrast images demonstrating homogenously enhancing spherical lesion that measured 2.4 × 2.1 × 2.2 cm with anterior pachymeningeal enhancement (red circle), and (D) perfusion scan of cerebral blood volume demonstrates relative value of 2.09 which was consistent with lymphoma.

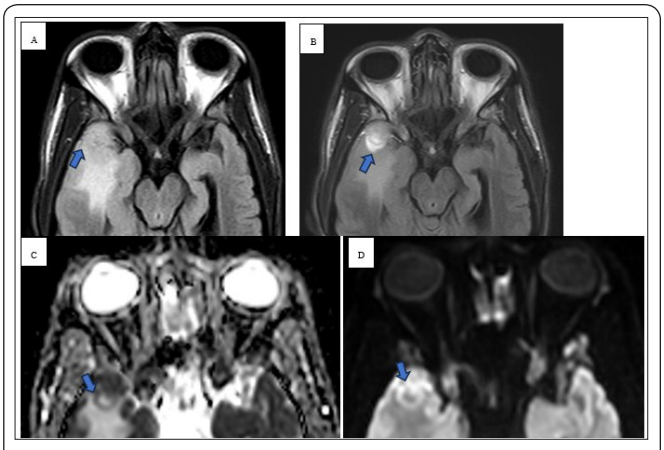

Figure 2: (A) Pre-T2 axial, and (B) Post-T2 axial contrast FLAIR images demonstrating anterior pachymeningeal enhancement, central hyperintensity, and peripheral hypointensity (blue arrow), (C) pretreatment MR imaging of brain with sb1000, and (D) with enhancement.

negative for recurrence of disease. Subsequently, the patient had progressive disease after 3 lines of therapy and deem stem cell transplant ineligible eventually transitioned to hospice and end of life care.

Case 2

28-year-old female with a history of three uncomplicated caesarean sections presented for neck swelling. On presentation she was found to have persistent cervical and axillary lymphadenopathy despite multiple trials of antibiotics. She underwent a right neck excisional lymph node biopsy which revealed cHL and histopathology showcasing interfollicular proliferation of large and multilobulated and single lobe cells with prominent nucleoli consistent with Reed-Sternberg cells. Immunohistochemical staining showed a diffuse positivity for CD15/30 with a Ki67 index of 80%. PET-CT neck demonstrated enlarged right neck cervical lymph nodes and MR brain demonstrating characteristic diffusion weighted images (DWI) with apparent diffusion coefficient (ADC) restrictions and T2 FLAIR enhancement within the frontal lobes (Figure 3 and figure 4). MRI of the chest, abdomen, and pelvis demonstrated right supraclavicular, retro clavicular, infraclavicular, right axillary, and right subpectoral lymph nodes. The initiation of chemotherapy was delayed due to pregnancy; the patient was in her third trimester and opted to start chemotherapy after delivery. During that period, she was monitored clinically. Subsequently, the patient started chemotherapy with ABVD. Later, she developed intermittent confusion with delusions for which brain imaging, CSF evaluation, extensive infectious, and paraneoplastic testing were obtained. Physical examination at this time was unremarkable except for pathological spread with finger flexion with biceps tendon reflex testing and brachioradialis reflex tendon testing bilaterally, but more pronounced with the brachioradialis reflex testing. All diagnostic workup was negative including a negative PET-CT scan after 2 cycles of chemotherapy. Chemotherapy was continued with omitting bleomycin per The United Kingdom Risk-Adapted Therapy in Hodgkin Lymphoma (RATHL) trial. The patient's neurological symptoms continued to improve with chemotherapy, and she was in complete remission at the end of chemotherapy. Follow up brain imaging indicated improvement in the leptomeningeal enhancement. After a few months the patient transferred medical care to another facility and thus the outcome of the case cannot be reported.

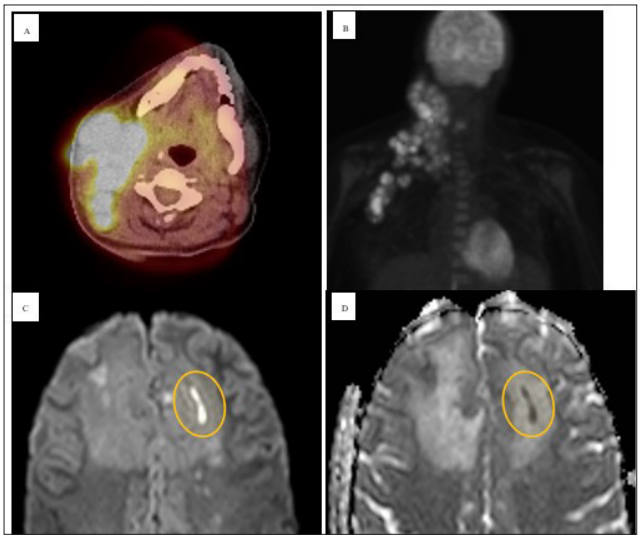

Figure 3: (A) Pretreatment PET-CT scan, (B) demonstrating fluoride-18 FDG metabolic uptake with bulky right cervical, supraclavicular, superior mediastinal, and axillary adenopathy, (C) axial MR imaging of brain demonstrating DWI, (D) with regional ADC restriction in bilateral frontal lobes and left parafalcine region adjacent to the left frontal horn (yellow circles).

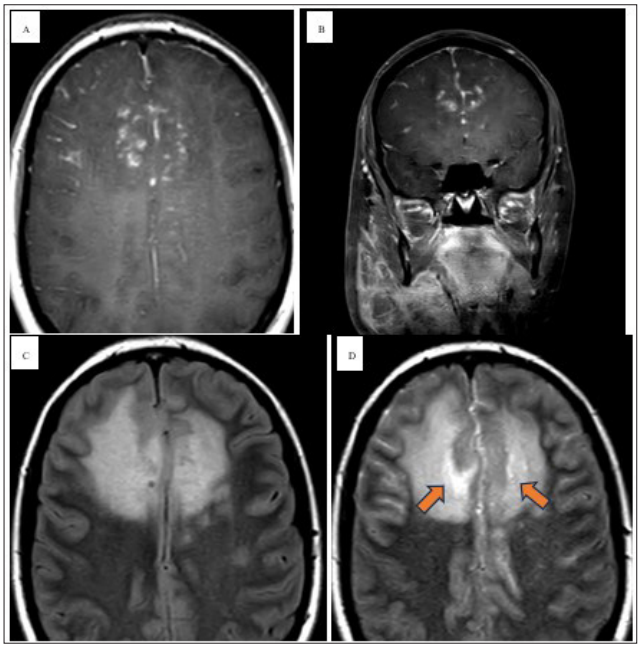

Figure 4: (A) Pretreatment post- axial, (B) coronal contrast T1 MRI that demonstrates leptomeningeal enhancement within the bifrontal lobes, predominantly within the parafalcine region, (C) pretreatment axial pre, and (D) post T2 FLAIR contrast enhancement within the bifrontal lobes (orange arrows).

Discussion

In patients with newly diagnosed or relapsed refractory cHL exhibiting neurological symptoms, an evaluation for potential direct and indirect involvement of the nervous system is necessary. CNS involvement occurs in only 0.01 - 0.5% of cases and any intracranial space-occupying lesion in a patient with a history of cHL demands consideration of secondary etiologies [10-13]. Intracranial cHL typically results from direct invasion from surrounding bony structures or perineural spread from cranial nerves [14]. Several case reports and series have been published in the literature and are summarized in table 1. Table 1 separates cases based on location of lesion, histological type, treatment type and EBV positivity. Though this table is not all-inclusive it summarizes the key findings that document remission in cases with appropriate treatment. The current first line chemotherapy regimens have minimal CNS penetration. The 5 years follow up on the ECHELON-2 trial showed a survival advantage with A-AVD compared to ABVD [15]. Further, the SWOG S1826 trial inducting progression free survival advantage with nivolumab as compared to brentuximab with AVD [16]. Probably, rapid control of the systemic disease aid to decrease risk of lymphomatous CNS involvement. However, this type of lymphoma is not well known to have CNS involvement. In

Table 1: Summary of intracranial HL cases reported in literature from 1998 to 2024.

Ref	Study/year	Age (yr)/sex	Location	Type	Outcome	EBV cases		EBV positive		Positive cases	Percentage positive
						Yes	No	Yes	No		
[17]	Deckert-Schluter et al.	62 F	Fronto-parietal lobe	LR	Excellent 13 months remission with XRT and CT	X	-	-	X	0	0
[18]	Figueroa et al.	23 F	Posterior fossa	NS	Excellent 3 months remission with XRT and CT	X	-	-	X	0	0
[19]	Subklewe and Anagnostopoulos	65 F	Temporal lobe	MC	Excellent 18 months remission with reduction of immunotherapy medications and XRT	X	-	X	-	1	1
[20]	Gerstner et al.	46 M, 72 M, 37 F, 19 M, 44 M, 23 M	N/A	N/A	5/8 patients are alive without disease progression at 10 months, only 2/8 alive at 35 months	X	-	X	-	4	0.25
[21]	Almhanna et al.	65 M	Temporal lobe	NS	Poor response, resection followed by XRT and CT	X	-	X	-	1	1
[22]	Torgerson et al.	79 F	Temporal lobe	NS	Poor response, received only XRT	X	-	-	X	0	0
[23]	Gessi et al.	77 M, 59 M, 65 F	Cerebellum, Brain stem, Temporal lobe	N/A	77 M – Excellent with XRT, NED, 59 M – N/A, 65 F – Excellent with CT, NED	X	-	X	-	2	0.67
[3]	van Blydenstein et al.	41 M	Parietal lobe	NS	Poor response, no treatment given, DOD	X	-	-	X	0	0
[24]	Szczepanek et al.	33 F	Temporal lobe and cerebellum	MC	Excellent, complete regression with XRT and CT	X	-	X	-	1	1

the relapse or refractory setting if the malignancy is driven by an infectious oncogene such as EBV, this very low risk CNS disease might increase.

Radiological findings

Radiologically, the first-line imaging modality should be a NCCT scan [14, 16]. Characteristic findings include a hyperattenuating lesion associated with edema, while immunocompromised patients may have a more heterogenous or even hypoattenuating appearance [14]. MRI reveals iso- to hypointense lesion(s) on T1 weighted scans and iso- to hyperintensity on T2 weighted images [17]. DWI in immunocompetent patients shows strong restricted diffusion with low ADC, however, lymphomatous spread in immunocompromised patients is more heterogenous with scattered lesions [18]. In high grade tumors and other metastatic tumors, there is high ADC due to significant vasogenic edema [16]. Table 1 involves cases which involve immunocompromised patients who show an equal mix of strong hyperintense weighted images and scattered lesions [3, 17-30].

Our immunocompromised patient in case 1 revealed peripheral restricted diffusion on DWI with T1 isotensity, T2/FLAIR central hyperintensity, and peripheral T2/FLAIR hypotensity (Figure 1 and figure 2). In a similar sense, case 2 demonstrated restricted diffusion on DWI and low ADC (Figure 3).

Infectious considerations

Brain absences occur from either a hematogenous spread, neighboring infective infiltration, or immunocompromised state. Mechanistically, brain abscesses begin as a focal area of cerebritis and form a fibrovascular capsule within 1-2 weeks [19]. Multiple studies reported specific features favoring brain abscesses including peripheral edema, central necrosis, extra parenchymal spread, and capsular enhancement. Peripheral edema, central necrosis, and extra parenchymal commonly produces short TE/short TR hypointensity with long TE/long TR hyperintensity with respect to CSF. Capsular features included short TE/short TR iso-to hyperintensity with long TE/long TR iso-to hypointensity secondary to paramagnetic hydroxyl free radicals produced by glial macrophages [20]. In addition to the above intra-axial abscesses commonly demonstrate enhanced signal on DWI and dimished ADC values. However, in instances of untreated abscesses, higher ADC signaling can be seen and therefore a premature closure of intracerebral malignancy may masquerade as an underlying abscess. A study using a high-resolution 3D gradient echo (susceptibility weighted imaging) sequence determined that 9/12 pyogenic abscess had features of the dual rim sign. This was defined as one ring most adjacent to a lesion being hyperintense and outermost rim being hypointense [19, 21].

Treatment

Lesions outside the blood-brain barrier (extra-axial, leptomeningeal and dural based lesions), are permeable to immunotherapy antibodies and chemotherapy drugs [17]. Due to a lack of clinical trials, there are no definitive treatment guidelines. Voorhees and Beaven [9] reviewed 16 patients undergoing varied therapies reported radiological evidence of treatment response in 11 patients and complete response in 9 patients [9] . It is essential to obtain tissue sampling for confirmatory diagnosis and to avoid administering corticosteroids preemptively, as retrospective studies have shown an increased rate of inconclusive biopsies following steroid use. In Case 1, the patient underwent a stereotactic brain biopsy confirming cHL. Subsequently, he was initiated on a dexamethasone taper followed by DHAP (dexamethasone, high dose cytarabine, and cisplatin). For refractory and relapsed cHL, novel therapies include pembrolizumab in combination with traditional

chemotherapy with liposomal doxorubicin, gemcitabine and vinorelbine (Pembro + GVD) which showed a curative rate prior to autologous hematopoietic stem cell transplant (Auto-SCT) of 93% [9]. Our patients received a combination of multiple regimens encompassing both traditional and novel therapies during and before the diagnosis of intracranial disease.

Conclusion

The key learning points from these cases are (1) to investigate all space-occupying lesions with confirmatory biopsy (2) to request comprehensive workup including neuroimaging with cHL exhibiting CNS symptoms to exclude secondary diseases processes such as infectious etiology and non-neoplastic mimics. Case reports with CNS involvement in various locations document complete remission with appropriate therapy. However, additional large-scale studies should be conducted for additional exploration of presentation, underlying pathophysiology and tailored treatment approaches.

Author Contributions

K.S., K.M., and D.P. wrote the initial manuscript; O.A., E.M., B.M., and M.P. provided critical feedback and supervised the project. All authors have read and agreed to the published version of the manuscript.

Acknowledgement

None.

Conflicts of Interest

Author O.A has research funding for the institution: Seagen and Bristol-Myers Squibb

Institutional Review Board Statement

The study was conducted in accordance with the declaration of Helsinki and approved by the Institutional Review Board of University of South Alabama (protocol code 24-015 and approved on January 24, 2024).

Informed Consent Statement

Patient consent was waived due to there being no more than minimal risk to the privacy of the individual subjects based on the presence of the required elements. In addition, it is not practicable to conduct research without access to the use of the PHI.

References

1. Kaseb H, Babiker HM, Doerr C. 2023. Hodgkin Lymphoma (Nursing). In StatPearls, StatPearls Publishing.
2. Guermazi A, Brice P, de Kerviler E, Fermé C, Hennequin C, et al. 2001. Extranodal Hodgkin disease: spectrum of disease. *Radiographics* 21(1): 161-79. https://doi.org/10.1148/radiographics.21.1.g01ja02161
3. van Blydenstein SA, Patel M, Philip V, Lakha A, Pather S, et al. 2014. Classical Hodgkin lymphoma involving the central nervous system (brain)–an unusual presentation. *Clin Case Rep* 2(3): 88-92. https://doi.org/10.1002/ccr3.66
4. Archana R, Kumar PS, Kishore A. 2018. Role of MRI in evaluation of ring enhancing lesions of brain in correlation with MR spectroscopy. *Int J Contemp Med Surg Radiol* 3(4): 33-37.
5. Schwartz KM, Erickson BJ, Lucchinetti C. 2006. Pattern of T2 hypointensity associated with ring-enhancing brain lesions can help to differentiate pathology. *Neuroradiology* 48(3): 143-149. https://doi.org/10.1007/s00234-005-0024-5
6. Grommes C, Rubenstein JL, DeAngelis LM, Ferreri AJ, Batchelor TT. 2019. Comprehensive approach to diagnosis and treatment of newly diagnosed primary CNS lymphoma. *Neuro Oncol* 21(3): 296-305. https://doi.org/10.1093/neuonc/noy192
7. von Tresckow B, Moskowitz CH. 2016. Treatment of relapsed and refractory Hodgkin Lymphoma. *Semin Hematol* 53(3): 180-185. https://doi.org/10.1053/j.seminhematol.2016.05.010
8. Vassilakopoulos TP, Asimakopoulos JV, Konstantopoulos K, Angelopoulou MK. 2020. Optimizing outcomes in relapsed/refractory Hodgkin lymphoma: a review of current and forthcoming therapeutic strategies. *Ther Adv Hematol* 11: 2040620720902911. https://doi.org/10.1177/2040620720902911
9. Voorhees TJ, Beaven AW. 2020. Therapeutic updates for relapsed and refractory classical hodgkin lymphoma. *Cancers* 12(10): 2887. https://doi.org/10.3390/cancers12102887
10. Bruno F, Pronello E, Bortolani S, Palmiero R, Melcarne A, et al. 2019. P14. 85 Brain metastasis from Hodgkin's Lymphoma: case report and literature review. *Neuro Oncol* 21(3): 387-388. https://doi.org/10.1093/neuonc/noz126.320
11. Wood NL, Coltman CA. 1973. Localized primary extranodal Hodgkin's disease. *Ann Intern Med* 78(1): 113-118. https://doi.org/10.7326/0003-4819-78-1-113
12. Sapozink MD, Kaplan HS. 1983. Intracranial Hodgkin's disease. A report of 12 cases and review of the literature. *Cancer* 52(7): 1301-1307. https://doi.org/10.1002/1097-0142(19831001)52:7%3C1301::aid-cncr2820520728%3E3.0.co;2-5
13. Grimm S, Chamberlain M. 2010. Hodgkin' s Lymphoma: a review of neurologic complications. *Adv Hematol* 2011(1): 624578. https://doi.org/10.1155/2011/624578
14. Chourmouzi D, Potsi S, Moumtzouoglou A, Papadopoulou E, Drevelegas K, et al. 2012. Dural lesions mimicking meningiomas: a pictorial essay. *World J Radiol* 4(3): 75-82. https://doi.org/10.4329/wjr.v4.i3.75
15. Horwitz S, O'connor OA, Pro B, Trümper L, Iyer S, et al. 2022. The ECHELON-2 Trial: 5-year results of a randomized, phase III study of brentuximab vedotin with chemotherapy for CD30-positive peripheral T-cell lymphoma. *Ann Oncol* 33(3): 288-298. https://doi.org/10.1016/j.annonc.2021.12.002
16. Herrera AF, LeBlanc ML, Castellino SM, Li H, Rutherford SC, et al. 2023. SWOG S1826, a randomized study of nivolumab (N)-AVD versus brentuximab vedotin (BV)-AVD in advanced stage (AS) classic Hodgkin lymphoma (HL). *J Clin Oncol* 41(17). https://doi.org/10.1200/JCO.2023.41.17_suppl.LBA4
17. Deckert-Schlüter M, Marek J, Šetlík M, Marková J, Pakos E, et al. 1998. Primary manifestation of Hodgkin's disease in the central nervous system. *Virchows Arch* 432(5): 477-481. https://doi.org/10.1007/s004280050195
18. Figueroa BE, Brown JR, Nascimento A, Fisher DC, Tuli S. 2004. Unusual sites of Hodgkin's lymphoma: CASE 2. Hodgkin's lymphoma of the CNS masquerading as meningioma. *J Clin Oncol* 22(20): 4228-4230. https://doi.org/10.1200/jco.2004.01.163
19. Subklewe M, Anagnostopoulos I. 2007. Radiologic and pathologic features of a posttransplantation primary central nervous system lym-

phoma demonstrating epstein-barr virus–positive hodgkin lymphoma. *Clin Lymphoma Myeloma* 7(8): 535-537. https://doi.org/10.3816/clm.2007.n.038

20. Gerstner ER, Abrey LE, Schiff D, Ferreri AJ, Lister A, et al. 2008. CNS Hodgkin lymphoma. *Blood* 112(5): 1658-1661. https://doi.org/10.1182/blood-2008-04-151563
21. Almhanna K, Wongchaowart N, Sweetenham J. 2009. Intracerebral Hodgkin's lymphoma in a patient with chronic lymphocytic leukemia/small lymphocytic lymphoma: a case report and literature review. *Cancer Invest* 27(2): 215-220. https://doi.org/10.1080/07357900802189824
22. Torgerson S, Olteanu H, Tinguely M, Fenske TS. 2011. Central nervous system Hodgkin lymphoma: case report and review of the literature. *J Neurooncol* 102(2): 329-334. https://doi.org/10.1007/s11060-010-0320-8
23. Gessi M, Kuchelmeister K, Kellner U, Ritter M, Morgner A, et al. 2013. Unusual clinico-pathological features in primary Hodgkin's lymphomas of the central nervous system. *Acta Neurochir* 155(1): 19-24. https://doi.org/10.1007/s00701-012-1535-6
24. Szczepanek D, Szumiło J, Stoma F, Szymczyk A, Jarosz B, et al. 2020. A case report of a female patient with Hodgkin lymphoma localized in the central nervous system and with concomitant pulmonary lymphomatoid granulomatosis. *Front Neurol* 11: 963. https://doi.org/10.3389/fneur.2020.00963
25. Fink KR, Fink JR. 2013. Imaging of brain metastases. *Surg Neurol Int* 4(4): 209-219. https://doi.org/10.4103/2152-7806.111298
26. Lyndon D, Lansley JA, Evanson J, Krishnan AS. 2019. Dural masses: meningiomas and their mimics. *Insights Imaging* 10(1): 11.
27. Scheichel F, Pinggera D, Popadic B, Sherif C, Marhold F, et al. 2022. An update on neurosurgical management of primary CNS lymphoma in immunocompetent patients. *Front Oncol* 12: 884724. https://doi.org/10.3389/fonc.2022.884724
28. Carloni A, Bernardini M, Mattei C, De Magistris AV, Llabres′ Diaz F, et al. 2022. Can MRI differentiate between ring′ enhancing gliomas and intra′ axial abscesses?. *Vet Radiol Ultrasoun* 63(5): 563-572. https://doi.org/10.1111/vru.13098
29. Haimes AB, Zimmerman RD, Morgello S, Weingarten K, Becker RD, et al. 1989. MR imaging of brain abscesses. *Am J Neuroradiol* 10(2): 279-291. https://doi.org/10.2214/ajr.152.5.1073
30. Toh CH, Wei KC, Chang CN, Hsu PW, Wong HF, et al. 2012. Differentiation of pyogenic brain abscesses from necrotic glioblastomas with use of susceptibility-weighted imaging. *Am J Neuroradiol* 33(8): 1534-1538. https://doi.org/10.3174/ajnr.a2986