Journal of Medical Imaging & Case Reports

https://doi.org/10.17756/micr.2025-117

Case Report

Open Access

Slipped Proximal Humeral Epiphysis

Daniel Reyes[1,2*], Jace Buxton[2,3] and Scott Jorgensen[2]

[1]*College of Medicine-Phoenix, University of Arizona, Phoenix, United States*
[2]*Department of Radiology, Phoenix Children's Hospital, Phoenix, United States*
[3]*Department of Radiology, Mayo Clinic Arizona, Phoenix, United States*

***Correspondence to:**
Daniel Reyes
College of Medicine-Phoenix,
University of Arizona,
Phoenix, United States.

Department of Radiology,
Phoenix Children's Hospital,
Phoenix, United States.
E-mail: danielreyes@arizona.edu;
danielr0819@yahoo.com

Received: April 12, 2025
Accepted: July 07, 2025
Published: July 11, 2025

Citation: Reyes D, Buxton J, Jorgensen S. 2025. Slipped Proximal Humeral Epiphysis. *J Med Imaging Case Rep* 9(1): 26-28.

Copyright: © 2025 Reyes et al. This is an Open Access article distributed under the terms of the Creative Commons Attribution 4.0 International License (CCBY) (http://creativecommons.org/licenses/by/4.0/) which permits commercial use, including reproduction, adaptation, and distribution of the article provided the original author and source are credited.

Published by United Scientific Group

Abstract

Background: Slipped proximal humeral epiphysis (SPHE) has rarely been described in the literature. In addition, to these authors' knowledge, this condition has not previously been described in the literature as occurring following a fall such as occurred in this case. This contributes a potential mechanism of injury to this uncommon finding.

Case: The patient was a 10-year-old male who presented with upper arm/shoulder pain and swelling after a fall in the shower. Upon initial x-ray imaging, he was found to have fracture of the metaphysis of the proximal right humerus with widening of the proximal humeral physis. Five-week follow up x-ray demonstrated healing changes of the proximal humeral fracture, with interval inferolateral displacement of the proximal humeral epiphysis relative to the humeral shaft.

Conclusion: SPHE may occur in an injury that involves fracture of the proximal humeral epiphysis, including in an uncommonly described setting for this type of injury.

Keywords

Salter-Harris type II fracture, Humeral head displacement, Humerus fracture, Epiphysiolysis

Introduction

SPHE describes the uncommon finding of displacement of the proximal humerus epiphysis in the setting of proximal humeral epiphysiolysis (PHE), a fracture of the proximal humeral epiphyseal plate that most commonly has been described in pre-adolescent/adolescent athletes, particularly baseball pitchers. SPHE has also been described in birth injuries as well as in cases of Ewing Sarcoma after radiation therapy [1-5]. Our case is an unusual presentation of SPHE involving a fall in the shower, which initially presented as non-displaced PHE treated conservatively, followed by SPHE identified on follow-up imaging five weeks later.

Case Report

Clinical summary

The patient is a 10-year-old male who presents with history of slipping and falling in the shower, and subsequent upper arm/shoulder pain and swelling. Pain was moderate and sharp, located over the right upper arm. There were no reported paresthesias, motor loss, nor other associated symptoms. Physical exam demonstrated a well-developed, well-nourished patient with no apparent distress. The

skin was intact without a visible lesion. There were palpable pulses, passive range of motion of the digits of the hand was full bilaterally, and there was no evidence of instability. There was moderate tenderness to palpation over the left humerus, and reduced range of motion with abduction and forward flexion of the right shoulder. Strength was normal and light touch intact in all nerve distributions. The patient was placed in a sling, and pain was well-controlled with sling and oral pain medications.

Imaging findings

Initial x-ray (Figure 1) demonstrated fracture of the metaphysis of the proximal right humerus with widening of the proximal humeral physis (Salter-Harris type II fracture). There was no evidence of glenohumeral joint dislocation. The acromioclavicular joint was normal.

Five-week follow up x-ray (Figure 2) demonstrated healing changes of the proximal humeral Salter-Harris type II fracture. There was interval slipping of the proximal humeral epiphysis, with inferolateral displacement of the epiphysis relative to the humeral shaft.

Differential diagnosis

Differential diagnosis considerations in shoulder area injury may include rotator cuff injury, biceps tendonitis, labral tear, impingement syndrome, shoulder dislocation, acromioclavicular joint separation, or other fracture of the humerus, scapula, or clavicle.

Discussion

PHE, which has alternatively been referred to as osteochondrosis of the proximal humeral epiphysis, involves fracture of the proximal humeral epiphyseal plate. PHE classically affects athletes, in particular baseball pitchers aged 11 - 16 years with non-fused growth plates, though it has also been described in other throwing athletes, as well as tennis players and gymnasts [1, 2]. In the setting of young throwing athletes, this has been referred to as Little League shoulder and involves a shear rotational stress injury and cartilage damage of the proximal humerus epiphyseal cartilage [1, 2]. The mechanism in this setting involves substantial torque placed on the humeral shaft during the final component of the arm-cocking phase of pitching motion prior to acceleration. This torque deforms the epiphyseal plate, which is weaker than the nearby ligaments, leading to injury [2]. Presentation of PHE in baseball pitchers involves progressive generalized shoulder pain with throwing [2]. One study found that of 41 youth baseball players aged 9 - 12 years with pain in their throwing arm who agreed to undergo x-ray, 36.6% had findings of PHE [1]. Other populations are more rarely affected by PHE, such as infants in the setting of a traumatic birth, in whom PHE reportedly occurs at a rate of 10.1/100,000 births [3]

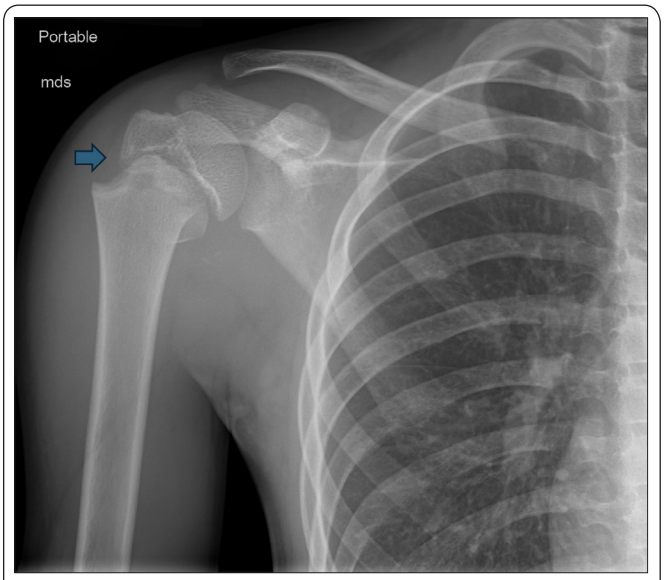

Figure 1: Initial x-ray demonstrated fracture of the proximal right humerus (Salter-Harris type II fracture) with widening of the proximal humeral physis (arrow). No evidence of glenohumeral joint dislocation. The acromioclavicular joint was normal.

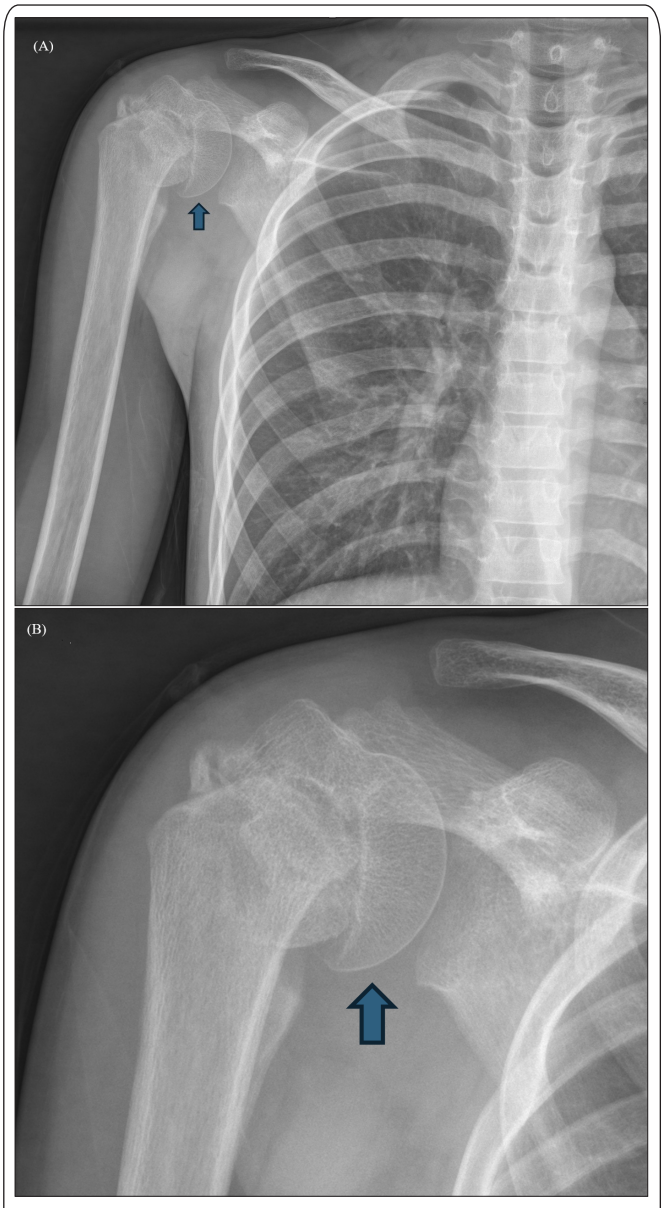

Figure 2: 5-week follow up x-ray demonstrated healing changes of the proximal humeral Salter-Harris type II fracture. There was interval slipping of the PHE (arrow), with inferolateral displacement of the epiphysis relative to the humeral shaft.

SPHE is a rare entity that involves displacement of the proximal humerus epiphysis in the setting of PHE. Fracture of the physis, with complete separation through the zone of hypertrophic cells, is accompanied by proximal humeral segment displacement [4]. SPHE has also been described as grade III PHE in one study [1]. SPHE has been described in association with similar mechanisms as PHE generally, including baseball pitching, birth trauma, and gymnastics [5-7]. A case described in 1994 was seen in an Olympic gymnast [6]. A 2013 report describes a 14-year-old boy who exceeded recommended limitations in baseball pitching by 50% [7]. Under five years of age, it is most commonly related to birth injury [4, 5]. The condition has been described with the utilization of radiotherapy, administered in combination with chemotherapy, for the treatment of Ewing Sarcoma; in 1982 two cases of radiation-associated SPHE were described as previously unreported radiotherapy complication [4]. Prior to this 1982 report, nine cases of slipped capital femoral epiphyses, an analogous injury involving the femur, were reportedly described in association with radiation therapy [4].

Treatment for PHE is generally conservative, including rest and sling immobilization with gradual return to activity and physical therapy [2, 8]. Closed reduction may be considered for fractures with significant displacement/angulation, and operative treatment may be considered with instability or other complications such as neurovascular complications [2, 8].

Imaging

Imaging of PHE generally involves radiographs, as were performed in our case, which demonstrate proximal humeral physis widening consistently with Salter-Harris or physeal fracture, in addition to demineralization and adjacent bone sclerosis and fragmentation, along with displacement in the case of SPHE [9].

Other imaging can be used to visualize PHE/SPHE. For example, magnetic resonance imaging (MRI) has been suggested as potentially diagnostic for PHE [10]. Epiphyseal plate widening represents the earliest and most common MRI finding in PHE. MRI may also demonstrate cystic change, sclerosis, demineralization, and physeal or metaphyseal fragmentation, consistent with chronicity of the injury in this condition [10].

Sonography can also be used to visualize SPHE, with one reported case of a SPHE due to birth injury presenting on ultrasound with widening and decreased sharpness of the epiphyseal plate, interruption/reduced smoothness of the transition of the proximal humerus metadiaphysis into the head, the caudal joint capsule appearing thicker and containing echoes (thought to potentially represent intra-articular thrombus), and lateral deltoid displacement [5].

As described above, our case demonstrated findings on radiography of a proximal humeral physeal fracture with metaphyseal involvement (Salter-Harris II), which occurred after a fall in the shower as the preceding injury, and with epiphyseal displacement identified on follow-up imaging.

Conclusion

SPHE is a rare manifestation of PHE in which there is displacement of the humeral head associated with epiphysiolysis. SPHE has previously been described in cases of pre-adolescents/adolescent baseball pitchers, birth injury, and radiation treatment. Primary imaging of SPHE consists of radiographs, which show widening of the proximal humeral physis and displacement of the humeral head, analogous to findings of slipped capital femoral epiphysis in the hip. Our case is an unusual presentation of SPHE involving a fall in the shower, which initially presented as non-displaced PHE treated conservatively, followed by SPHE identified on follow-up imaging five weeks later.

Acknowledgements

None.

Conflict of Interest

None.

References

1. Kanematsu Y, Matsuura T, Kashiwaguchi S, Iwase T, Suzue N, et al. 2015. Epidemiology of shoulder injuries in young baseball players and grading of radiologic findings of little leaguer's shoulder. *J Med Invest* 62(3-4): 123-125. https://doi.org/10.2152/jmi.62.123
2. Casadei K, Kiel J. 2025. Proximal Humeral Epiphysiolysis. In StatPearls. StatPearls Publishing, Treasure Island (FL).
3. Teles BN, Castro JC, Ovídeo J. 2024. Proximal humerus epiphysiolysis as a rare cause of fracture in childbirth - a case report. *Rev Bras Ortop (Sao Paulo)* 59(S2): e243-e246. https://doi.org/10.1055/s-0044-1779330
4. Edeiken BS, Libshitz HI, Cohen MA. 1982. Slipped proximal humeral epiphysis: a complication of radiotherapy to the shoulder in children. *Skeletal Radiol* 9(2): 123-125. https://doi.org/10.1007/bf00360496
5. Zieger M, Dörr U, Schulz RD. 1987. Sonography of slipped humeral epiphysis due to birth injury. *Pediatr Radiol* 17(5): 425-426. https://doi.org/10.1007/bf02396624
6. Dalldorf PG, Bryan WJ. 1994. Displaced Salter-Harris type I injury in a gymnast. A slipped capital humeral epiphysis?. *Orthop Rev* 23(6): 538-541.
7. Ballinger J. 2025. Slipped Proximal Humeral Epiphysis. [https://radiopaedia.org/cases/slipped-proximal-humeral-epiphysis?lang=us] [Accessed July 10, 2025]
8. Traumatic Conditions (Other): Slipped Upper Humeral Epiphysis. [https://www.rcemlearning.co.uk/modules/shoulder-and-brachial-plexus/lessons/management-50/topic/traumatic-conditions-other-slipped-upper-humeral-epiphysis/] [Accessed July 10, 2025]
9. Iqbal S, Kogan J, Bell D. 2024. Little League Shoulder. [https://radiopaedia.org/articles/little-league-shoulder] [Accessed July 10, 2025]
10. Hatem SF, Recht MP, Profitt B. 2006. MRI of little leaguer's shoulder. *Skeletal Radiol* 35(2): 103-106. https://doi.org/10.1007/s00256-005-0015-y